

Christoph Robier*, Carolin Körber, Franz Quehenberger, Manfred Neubauer and Albert Wölfler

The frequency of occurrence of fish-shaped red blood cells in different haematologic disorders

<https://doi.org/10.1515/cclm-2017-0378>

Received May 3, 2017; accepted June 9, 2017; previously published online July 21, 2017

Abstract

Background: Red blood cells (RBC) resembling the silhouette of a fish are rarely observed in peripheral blood (PB) smears. In this study, we determined the frequency of occurrence of fish-shaped RBC in different haematologic diseases.

Methods: We examined PB smears of patients with iron deficiency anaemia (IDA) (n=23), β -thalassaemia minor (BTM) (n=30), sickle cell disease (SCD) (n=7), autoimmune haemolytic anaemia (AIHA) (n=13), microangiopathic haemolytic anaemia (MAHA) (n=11), hereditary spherocytosis (HS) (n=4), hereditary elliptocytosis (HE) (n=3), vitamin B12 and folate deficiency (n=15), anaemia in liver disease (LD) (n=17), myelodysplastic syndrome (MDS) (n=15), acute myeloid leukaemia (AML) (n=29), chronic myeloid leukaemia (CML) (n=18), primary myelofibrosis (PMF) (n=12), chronic myelo-monocytic leukaemia (CMML) (n=15) and 21 healthy controls by light microscopy for the occurrence of fish-shaped erythrocytes. The fish-shaped RBC were counted as cells per 20 high-power fields (HPF) at 1000-fold magnification, and slides containing ≥ 1 fish-shaped RBC/20 HPF were regarded as positive.

Results: Fish-shaped RBC were significantly found in HE, iron deficiency, vitamin B12/folate deficiency, LD and PMF. The highest numbers of fish-shaped RBC were seen in HE and vitamin B12/folate deficiency. In patients with BTM, MDS, AML and CMML, this RBC anomaly was only occasionally observed. Furthermore, a statistically significant

negative correlation of haemoglobin with the occurrence of fish-shaped RBC was apparent ($p < 0.014$).

Conclusions: Our data show that the occurrence of fish-shaped RBC is suggestive of a pathologic condition, especially IDA, HE, vitamin B12 or folate deficiency, primary myelofibrosis or LD, and is significantly associated with severity of anaemia.

Keywords: erythrocytes; fish cells; fish-shaped erythrocytes; poikilocytes; red blood cell morphology.

Introduction

In peripheral blood (PB) films examined in laboratory routine, red blood cells (RBC) resembling the silhouette of a fish are rarely observed. Such “fish cells” have been described as being similar to tear-drop cells, having one round and one tapered end, but unlike tear-drop poikilocytes, the tapered end flares out into two buds looking like a fish’s tail [1]. According to our own observations, the body of the fish cells may appear spheroidal or oval, and the margins of the fins may be serrated or straight. Figure 1 shows typical examples of fish-shaped RBC from our study population. To our knowledge, a systematic description or definition of this type of poikilocyte as well as data on its association with certain haematologic disorders have not been published to date.

We present data from a study which was performed to determine the frequency of occurrence of fish-shaped RBC in different haematologic diseases in order to identify a potential association with specific disorders.

Materials and methods

We examined PB films obtained from inpatients and outpatients with iron deficiency anaemia (IDA, n=23), β -thalassaemia minor (BTM, n=30), sickle cell disease (SCD, n=7), autoimmune haemolytic anaemia (AIHA, n=13), microangiopathic haemolytic anaemia (MAHA, n=11), hereditary spherocytosis (HS, n=4), hereditary elliptocytosis (HE, n=3), vitamin B12 and folate deficiency (n=15), anaemia in liver disease (LD, n=17), myelodysplastic syndrome (MDS, n=15), acute myeloid leukaemia (AML, n=29), chronic myeloid leukaemia (CML, n=18), primary myelofibrosis (PMF, n=12), chronic myelo-monocytic leukaemia (CMML, n=15) and 21 healthy control subjects.

***Corresponding author: Christoph Robier**, MD, PD, Institute of Laboratory Diagnostics, Hospital of the Brothers of St. John of God, Bergstr. 27, 8020 Graz, Austria, Phone: +43 316 5989 26671, Fax: +43 316 5989 21505, E-mail: christoph.robier@bbgraz.at; and Clinical Institute of Medical and Chemical Laboratory Diagnostics, Medical University of Graz, Graz, Austria

Carolin Körber: Medical University of Graz, Graz, Austria

Franz Quehenberger: Institute of Medical Informatics, Statistics and Documentation, Medical University of Graz, Graz, Austria

Manfred Neubauer: Department of Internal Medicine, Hospital of the Brothers of St. John of God, Graz, Austria

Albert Wölfler: Division of Hematology, Medical University of Graz, Graz, Austria

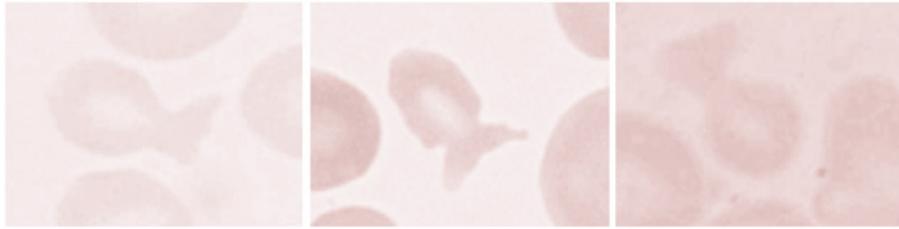


Figure 1: Examples of fish-shaped erythrocytes (May-Grünwald-Giemsa stain, 1000-fold magnification, oil immersion).

The demographic and laboratory characteristics of the study population are described in detail in Table 1.

The RBC indices were determined by an ADVIA 2120i haematology analyser (Siemens Healthcare Diagnostics Ltd., Vienna, Austria) according to the manufacturer's instructions. The haematology analyser was constantly checked by internal controls and external quality assurance programs.

PB was obtained by venepuncture into a Sarstedt Monovette™ with ethylene diamine tetraacetic acid (2.7 mL K₂EDTA, Sarstedt, Nuembrecht, Germany) as anticoagulant. After blood drawing, the samples were kept at room temperature and the PB smears were made within a maximum of 2 h. PB smears were prepared according to the standardised operating procedure of our Laboratory Institute by specially trained members of the technical staff. The blood films were manually spreaded on clean and grease-free glass slides, dried at room temperature for at least 30 min and were stained according to the May-Grünwald-Giemsa technique. After preparation, the slides were coded by a person not involved in microscopic analysis, and were finally examined in a blinded fashion by light microscopy by an experienced analyst. The analyst checked the slides for the occurrence of typical storage-induced artefacts such as crenation or echinocytic changes in RBC, degeneration of neutrophils or lobulation of

lymphocyte nuclei in order to decide whether the blood smears were suitable for being included in the study [2]. The fish-shaped RBC, defined according to the description above and depicted in Figure 1, were counted as cells per 20 high-power fields (HPF) at 1000-fold magnification. In contrast to schistocytes, which are well established as typical morphological substrates for distinct disorders such as thrombotic microangiopathies, with a defined threshold value of 1% schistocytes of the RBC in absence of additional severe RBC abnormalities [3], fish-shaped erythrocytes have not been associated to certain diseases to date. Based on our own observations in clinical laboratory routine, showing that fish-shaped RBCs are usually apparent solely sporadic in positive cases, we determined the cell count as fish cells per 20 HPF at 1000-fold magnification. As one HPF contains about 200 RBCs, 20 HPF contain approximately 4000 RBC, which offers a higher chance to detect rare abnormalities. This approach is supported by a previous study proposing to examine a minimum of 1000–5000 RBC in a proper area of the PB smear to achieve an adequate precision [4]. In order to prove our approach, we re-examined all slides which were initially found to be positive at examination of 20 HPF per slide and determined the fish-shaped RBC per 1000 RBC. Thereby we observed that only 31.6% (n = 12) of the slides which were positive for fish-shaped RBCs per 20 HPF at 1000-fold magnification

Table 1: Basic characteristics of the study population.

Disease	n	Age, years	Female sex	Hb, mmol/L	MCH, pg	MCV, fL
IDA	23	72 (37–90)	15 (65.2)	5.3 (1.9–7.1)	72 (50–80)	22 (11–25)
BTM	30	31 (1–56)	13 (43.3)	7.9 (6.8–9.1)	68 (58–76)	21 (18–25)
SCD	7	37 (32–52)	4 (80)	6.7 (5.2–7.4)	68 (60–95)	24 (20–34)
AIHA	13	72 (24–82)	9 (69.2)	5.2 (2.9–8.3)	98 (77–114)	31 (30–40)
MAHA	11	62 (34–81)	6 (54.5)	5.2 (4.0–6.7)	91 (82–105)	31 (28–37)
HS	4	58 (21–73)	1 (25)	7.1 (5.8–9.0)	88 (79–91)	32 (30–35)
HE	3	80 (74–89)	1 (33.3)	7.0 (6.5–8.5)	88 (88–90)	32 (31–32)
Vit B12/folate deficiency	15	75 (32–91)	7 (46.7)	5.5 (3.5–8.1)	116 (95–132)	40 (32–51)
LD	17	70 (42–87)	9 (52.9)	6.3 (5.4–7.6)	104 (96–114)	34 (29–38)
MDS	15	75 (61–88)	8 (53.3)	6.0 (4.4–7.4)	91 (73–110)	31 (22–36)
AML	29	77 (49–90)	18 (64.3)	5.7 (3.0–7.8)	92 (74–111)	32 (24–39)
CML	18	65 (36–77)	6 (37.5)	7.6 (4.2–10.2)	89 (73–101)	29 (22–33)
PMF	12	74 (52–84)	4 (33.3)	6.9 (3.9–11.1)	89 (77–104)	29 (23–32)
CMML	15	79 (51–94)	3 (21.4)	6.8 (5.1–10.0)	87 (79–106)	29 (25–40)
Controls	21	70 (35–90)	13 (61.9)	8.8 (8.0–10.4)	90 (85–97)	30 (27–33)

IDA, iron deficiency anaemia; BTM, beta thalassaemia minor; SCD, sickle cell disease; AIHA, autoimmune haemolytic anaemia; MAHA, microangiopathic haemolytic anaemia; HS, hereditary sphaerocytosis; HE, hereditary elliptocytosis; LD, liver disease; MDS, myelodysplastic syndrome; AML, acute myeloid leukaemia; CML, chronic myeloid leukaemia; PMF, primary myelofibrosis; CMML, chronic myelomonocytic leukaemia; Hb, haemoglobin; MCH, mean corpuscular haemoglobin; MCV, mean corpuscular volume. Age, Hb, MCH and MCV are expressed as median (range), and female sex is expressed as n (%).

were positive when applying the 1000 RBC threshold proposed for the counting of schistocytes by the International Council for Standardization in Haematology (ICSH) [3].

Slides containing one or more fish-shaped RBC per 20 HPF at 1000-fold magnification were defined as positive for this morphological RBC abnormality.

Statistical data analysis was performed with the package R 3.2 (www.r-project.org) and the coin 1.1–3 package. Group comparisons of the occurrence of fish-shaped RBC between the disease groups and the controls were assessed by Fisher's exact test. A potential association of the severity of anaemia, represented by the parameter haemoglobin, with the number of fish-shaped RBC, was determined by using the stratified Spearman correlation. *p*-Values <0.05 were regarded as statistically significant. This study was approved by the Ethics Committee of the Hospital of the Brothers of St. John of God Graz and was performed in accordance with the Declaration of Helsinki.

Results

The results are presented in detail in Table 2. Overall, fish-shaped erythrocytes were found in patients with HE, IDA,

Table 2: Occurrence of fish-shaped red blood cells in various haematologic disorders and controls.

Disease	n	Fish-shaped red blood cells		p-Value
		Positivity, n (%)	Number, median (range) ^a	
IDA	23	10 (43.5)	0 (0–2)	0.0006
BTM	30	2 (6.7)	0 (0–1)	0.51
SCD	7	0	0	1
AIHA	13	0	0	1
MAHA	11	0	0	1
HS	4	0	0	1
HE	3	3 (100)	3 (2–6)	0.00049
Vit B12/folate deficiency	15	8 (53.3)	1 (0–4)	0.00021
LD	17	5 (29.4)	0 (0–2)	0.012
MDS	15	1 (6.7)	0 (0–2)	0.42
AML	29	3 (10.7)	0 (0–1)	0.25
CML	18	0	0	1
PMF	12	5 (41.7)	0 (0–2)	0.0033
CMML	15	1 (7.1)	0 (0–2)	0.4
Controls	21	0	0	

IDA, iron deficiency anaemia; BTM, beta thalassaemia minor; SCD, sickle cell disease; AIHA, autoimmune haemolytic anaemia; MAHA, microangiopathic haemolytic anaemia; HS, hereditary sphaerocytosis; HE, hereditary elliptocytosis; LD, liver disease; MDS, myelodysplastic syndrome; AML, acute myeloid leukaemia; CML, chronic myeloid leukaemia; PMF, primary myelofibrosis; CMML, chronic myelo-monocytic leukaemia. ^aThe number of fish-shaped red blood cells is expressed as cells per 20 HPF at 1000-fold magnification.

vitamin B12/folate deficiency, LD, BTM, MDS, PMF, AML and CMML. Compared to the control subjects, their occurrence was statistically significant in HE, IDA, vitamin B12/folate deficiency, LD and PMF. In patients with BTM, MDS, AML and CMML, fish-shaped RBC were apparent in low percentages of the samples, but no statistically significant difference compared to the controls was found. The highest numbers of fish-shaped cells were seen in patients with HE and vitamin B12/folate deficiency. The blood films from the control subjects as well as from patients with SCD, MAHA, AIHA, CML and HS were all negative. Furthermore, a statistically significant negative correlation of haemoglobin, independent from the underlying disorder, with the occurrence of fish-shaped RBC, was observed (*p* < 0.014).

Discussion

The purpose of this study was to determine the frequency of occurrence of fish-shaped RBC in different haematologic diseases in order to identify a potential association with specific disorders.

Based on our observations, three major conclusions can be drawn. First, our findings suggest that fish-shaped RBC are not observed in PB smears of healthy persons and that the occurrence of these poikilocytes may thus indicate a pathologic condition.

Second, fish-shaped RBC were mainly observed in certain disorders such as IDA, HE, vitamin B12 or folate deficiency, PMF and LD with the highest numbers of cells per 20 HPF in patients with HE and vitamin B12 or folate deficiency, but only in single subjects with MDS, CMML, AML and BTM.

In an extensive review of the literature including standard books on blood cell morphology [2, 5] and papers on that topic screened by PubMed [6], we did not find a systematic description of this certain type of poikilocyte. In a review on red blood cell morphology, Ford mentioned “fish cells” as first described by Barbara Bain in a personal communication. In that review, fish-shaped RBC were reported as poikilocytes seen in thalassaemia, but generally not in iron deficiency or anaemia of chronic disease [1]. This statement is not in accordance with our data, because in our study population the fish cells were more frequently found in patients with IDA (*n* = 10, 43.5%, *p* = 0.0006 compared to controls) than with beta thalassaemia trait (*n* = 2, 6.7%, *p* = 0.51 compared to controls). In one report on the occurrence of mushroom-shaped RBC in a case of HS with a protein band-3 deficiency, the

author provided several images of poikilocytes, some of them resembling the shape of fishes, and reported that mushroom-, fish/whale-, puzzle- or yeast-shaped erythrocytes may be associated with band-3 deficiency and can also be observed after myelofibrosis and occasionally in nonspecific dyserythropoiesis [7]. In our four patients with HS, which were, however, not tested for band-3 deficiency, we did neither observe fish- nor mushroom-shaped RBC.

Third, fish-shaped RBC were significantly associated with severity of anaemia, the occurrence of fish-shaped RBC may thus point to a more severe state of disease.

This study had a limitation that merits mention. Based on the relatively small sample size and as some diseases were underrepresented, further investigations incorporating data from larger study populations are needed to confirm our findings and especially to examine a potential role of this type of poikilocyte in the differential diagnosis of anaemia or in the risk assessment of anaemia in clinical laboratory routine.

In summary, our data show that fish-shaped RBC represent a shape anomaly suggestive of a pathologic condition, which may occur in different haematologic disorders, especially in IDA, HE, vitamin B12 or folate deficiency, PMF and LD, and are associated with severity of anaemia.

Acknowledgments: The authors are grateful to the haematology team of the Central Laboratory of the Hospital of the Brothers of St. John of God in Graz for the excellent technical support.

Author contributions: C.R. is the principal investigator and he designed the study, performed microscopic examinations and wrote the manuscript; K.C., F.Q., M.N. and A.W. contributed to designing the study, conducting the work, interpreting the results and editing of the manuscript. All the authors have accepted responsibility for the entire content of this submitted manuscript and approved submission.

Research funding: None declared.

Employment or leadership: None declared.

Honorarium: None declared.

Competing interests: The funding organization(s) played no role in the study design; in the collection, analysis, and interpretation of data; in the writing of the report; or in the decision to submit the report for publication.

References

1. Ford J. Red blood cell morphology. *Int J Lab Hem* 2013;35:351–7.
2. Bain BJ. *Blood Cells. A practical guide*, 5th ed. Chichester, West Sussex, UK: Blackwell, 2015:72–98.
3. Zini G, D’Onofrio G, Briggs C, Erber W, Jou JM, Lee SH, et al. ICSH recommendations for identification, diagnostic value, and quantification of schistocytes. *Int J Lab Hem* 2012;34:107–16.
4. Lesesve JF, Salignac S, Lecompte T. Laboratory measurement of schistocytes. *Int J Lab Hem* 2007;29:149–51.
5. D’Onofrio G, Zini G. *Morphology of blood disorders*, 2nd ed. Chichester, West Sussex, UK: Wiley Blackwell, 2015:99–138.
6. Bain BJ. Diagnosis from the blood smear. *N Engl J Med* 2005;335:498–507.
7. Lesesve JF. Mushroom-shaped red blood cells in protein band-3 deficiency. *Am J Hematol* 2011;86:694.