

Porphyria Diagnostics—Part 1: A Brief Overview of the Porphyrias

UNIT 17.20

Vaithamanithi-Mudumbai Sadagopa Ramanujam¹ and Karl Elmo Anderson^{1,2}

¹Department of Preventive Medicine and Community Health, The University of Texas Medical Branch, Galveston, Texas

²Porphyria Research Center, The University of Texas Medical Branch, Galveston, Texas

Porphyria diseases are a group of metabolic disorders caused by abnormal functioning of heme biosynthesis enzymes and characterized by excessive accumulation and excretion of porphyrins and their precursors. Precisely which of these chemicals builds up depends on the type of porphyria. Porphyria is not a single disease but a group of nine disorders: acute intermittent porphyria (AIP), hereditary coproporphyria (HCP), variegate porphyria (VP), δ -aminolevulinic acid dehydratase deficiency porphyria (ADP), porphyria cutanea tarda (PCT), hepatoerythropoietic porphyria (HEP), congenital erythropoietic porphyria (CEP), erythropoietic protoporphyria (EPP), and X-linked protoporphyria (XLP). Each porphyria results from overproduction of heme precursors secondary to partial deficiency or, in XLP, increased activity of one of the enzymes of heme biosynthesis. Taken together, all forms of porphyria afflict fewer than 200,000 people in the United States. Based on European studies, the most common porphyria, PCT, has a prevalence of 1 in 10,000, the most common acute porphyria, AIP, has a prevalence of \sim 1 in 20,000, and the most common erythropoietic porphyria, EPP, is estimated at 1 in 50,000 to 75,000. CEP is extremely rare, with prevalence estimates of 1 in 1,000,000 or less. Only six cases of ADP are documented. The current porphyria literature is very exhaustive and a brief overview of porphyria diseases is essential in order for the reader to better appreciate the relevance of this area of research prior to undertaking biochemical diagnostics procedures. This unit summarizes the current knowledge on the classification, clinical features, etiology, pathogenesis, and genetics of porphyria diseases. © 2015 by John Wiley & Sons, Inc.

Keywords: Porphyria • overview • clinical features • etiology • pathogenesis

How to cite this article:

Ramanujam, V-M.S. and Anderson, K.E. 2015. Porphyria diagnostics—Part 1: A brief overview of the porphyrias. *Curr. Protoc. Hum. Genet.* 86:17.20.1-17.20.26.
doi: 10.1002/0471142905.hg1720s86

INTRODUCTION

This overview of the clinical features, etiology genetics, classification, and pathogenesis of the porphyrias provides the background needed to understand the importance of biochemical procedures for diagnosing these diseases.

The porphyrias are a group of at least nine metabolic disorders caused by alterations in enzymes involved in heme biosynthesis (Fig. 17.20.1). The terms porphyrin and porphyria are derived from the Greek word por-

phyrus, meaning purple. Urine from porphyria patients may be dark or reddish in color due to the presence of excess porphyrins and related substances, and may darken further after exposure to light. Porphyrias differ considerably from each other, but a common feature in all porphyrias is the accumulation in the body of porphyrins or porphyrin precursors. Although these are normal body chemicals, such accumulation is not normal. Precisely which of these chemicals builds up depends on the type of porphyria (Anderson et al.,

Biochemical
Genetics

17.20.1

Supplement 86



Current Protocols in Human Genetics 17.20.1-17.20.26, July 2015

Published online July 2015 in Wiley Online Library (wileyonlinelibrary.com).

doi: 10.1002/0471142905.hg1720s86

Copyright © 2015 John Wiley & Sons, Inc.

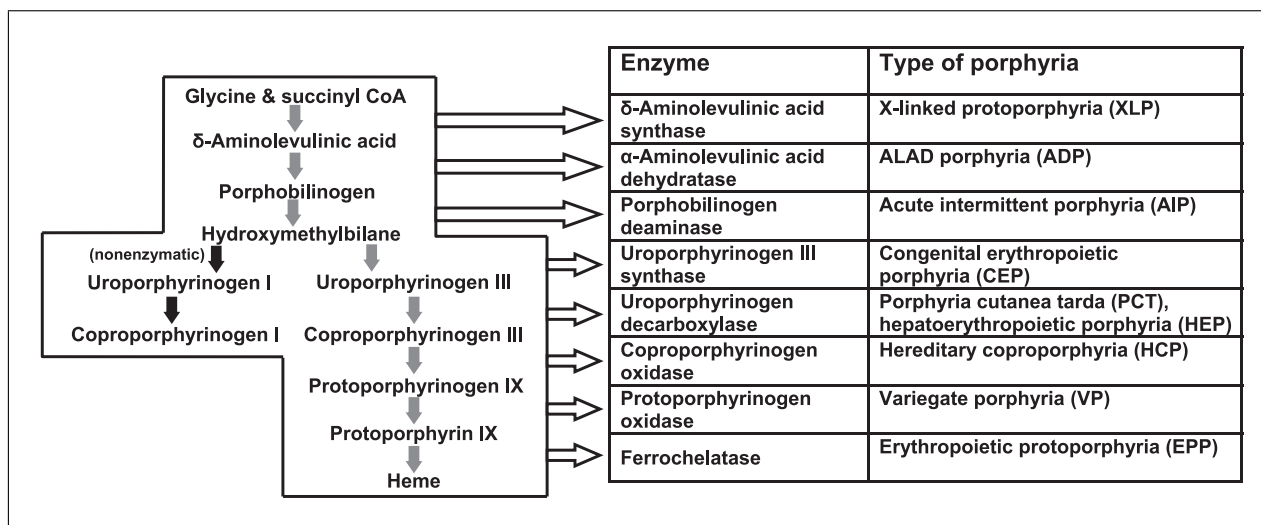


Figure 17.20.1 The heme biosynthetic pathway showing intermediates, enzymes, and associated porphyria diseases.

1981; Anderson, 2003, 2014; Desnick et al., 2013).

Each porphyria results from altered activity of a specific enzyme of the heme biosynthetic pathway, leading to overproduction of heme precursors (Bonkovsky et al., 1990; Hahn and Bonkovsky, 1998; Anderson et al., 2011). Enzyme activity is diminished in all but one of the porphyrias; in XLP, increased activity is a consequence of gain-of-function mutations of the first enzyme in the pathway (Ducamp et al., 2013).

CLASSIFICATION, INHERITANCE, AND PREVALENCE OF PORPHYRIAS

Heme precursors in the various porphyrias initially accumulate in either the liver or bone marrow, which are the tissues most active in heme biosynthesis. This is the basis for classification of porphyrias as either *hepatic* or *erythropoietic*. The major clinical manifestations of porphyrias are either neurologic, usually in the form of acute attacks, or cutaneous, resulting from phototoxicity. Based on these differences, porphyrias are classified as *acute* or *cutaneous*, with two types falling into both categories. The classifications and major clinical features of the various porphyrias are summarized in Table 17.20.1.

Mutations in the genes that encode enzymes of the heme biosynthetic pathway cause all porphyrias except for PCT, in which mutations for the affected enzyme are found in a minority of cases. One case of CEP was caused by a mutation of the transcription factor GATA-1 (Phillips et al., 2007b,c; Puy et al., 2010). Autosomal dominant inheritance with low pene-

trance is seen in AIP, HCP, VP, EPP, and the familial form of PCT. Homozygous cases of these disorders have been described, including for HEP, which is the homozygous form of familial PCT. Autosomal recessive inheritance is seen in ADP, CEP, and EPP. X-linked inheritance is seen in XLP.

Porphyrias are considered rare diseases in the United States, because they afflict fewer than 200,000 people. However, their prevalence is difficult to estimate. In Europe, the prevalence of the three most common porphyrias (PCT, AIP, and EPP) is estimated to be 1 in 10,000, 1 in 20,000, and 1 in 50,000 to 75,000, respectively. CEP is extremely rare, with prevalence estimates of 1 in 1,000,000 or less. Only six cases of ADP are documented (Deybach et al., 2006; Elder et al., 2013; also see <http://www.porphyrria-europe.org>). Hepatic porphyrias rarely cause clinical manifestations before puberty. Because erythropoietic porphyrias are generally symptomatic early in life, EPP is the most common porphyria in childhood, and is also the one associated with the longest delays in diagnosis.

The European Porphyria Network (<http://www.porphyrria-europe.org>) estimated prevalences based on newly diagnosed cases (335 patients from 11 countries) collected prospectively over a three-year period (Deybach et al., 2006; Elder et al., 2013). Prevalence was calculated from the incidence and mean disease duration. The incidence of hepatocellular carcinoma (HCC) in acute hepatic porphyria and the prevalence of patients with recurrent acute attacks of porphyria were also investigated (Innala and Andersson, 2011). The incidence of symptomatic AIP was similar in all countries

Table 17.20.1 Classifications and Principal Clinical Features of Porphyria Diseases

Porphyria	Classification	Principal clinical features
Acute intermittent porphyria (AIP)	Hepatic; acute	Neurological
Hereditary coproporphyria (HCP)	Hepatic; acute and cutaneous	Neurological; blistering photosensitivity (uncommon)
Variegate porphyria (VP)	Hepatic; acute and cutaneous	Neurological; blistering photosensitivity (common)
δ -Aminolevulinic acid dehydratase porphyria (ADP)	Hepatic; acute	Neurological
Porphyria cutanea tarda (PCT)	Hepatic; cutaneous	Blistering photosensitivity
Hepatoerythropoietic porphyria (HEP)	Hepatic; cutaneous	Blistering photosensitivity
Congenital erythropoietic porphyria (CEP)	Erythropoietic; cutaneous	Neurological
Erythropoietic protoporphyria (EPP)	Erythropoietic; cutaneous	Non-blistering photosensitivity
X-linked protoporphyria (XLP)	Erythropoietic; cutaneous	Non-blistering photosensitivity

(0.13 per million per year; 95% confidence interval [CI]: 0.10-0.14) except Sweden (0.51; 95% CI: 0.28-0.86). The incidence ratio for symptomatic AIP:VP:HCP was 1.00:0.62:0.15. The prevalence of AIP (5.4 per million; 95% CI: 4.5-6.3) was about half that previously reported (Badminton et al., 2014; Orphanet Report Series, 2014, http://www.orpha.net/orphacom/cahiers/docs/GB/Prevalence_of_rare_diseases_by_alphabetical_list.pdf). The prevalence of EPP was less uniform between countries, and in some countries exceeded previous estimates. Fourteen new cases of HCC (eleven from Sweden) were reported in patients with acute porphyria. Sixty seven patients (3 VP: 1 female, 2 males; 64 AIP: 53 females, 11 males) with recurrent attacks of acute porphyria were identified. The estimated percentage of patients with AIP that will develop recurrent acute attacks was 3-5%. The data suggest that the prevalence of symptomatic acute porphyria may be decreasing, possibly due to improved management or less exposure to harmful drugs, whereas the prevalence of EPP may be increasing due to improved diagnosis and greater recognition.

Phototoxicity due to excess porphyrins in the skin or dermal blood vessels may occur in all porphyrias except ADP and AIP. This is understandable, because the enzyme deficiencies in these two porphyrias precede porphyrin formation. However, photosensitivity develops even in AIP if complicated by advanced renal disease, which precludes urinary excre-

tion of excess porphyrins. In most cutaneous porphyrias, porphyrin-induced photosensitivity causes chronic skin fragility and formation of vesicles or bullae on light-exposed skin. In contrast, a painful acute and non-blistering type of photosensitivity is seen in EPP and XLP or acute erythema with burning and itching, but with less chronic injury. Light that corresponds to the Soret band (300-500 nm) maximally photoactivates porphyrins and passes through window glass; therefore, porphyric patients are not fully protected from skin photosensitivity by remaining indoors or in automobiles. In contrast, sunburn reactions result from light of shorter wavelength (290 to 320 nm), which is absorbed by window glass. Release of mediators and enzymes from mast cells and polymorphonuclear leukocytes and activation of complement contribute to inflammatory responses in patients with cutaneous porphyrias after light exposure (Bonkovsky, 1982; Bloomer and Bonkovsky, 1989; Anderson, 2003; Bloomer et al., 2005; also see American Porphyria Foundation, <http://www.porphyrifoundation.com/testing-for-porphyrin>).

ACUTE HEPATIC PORPHYRIAS

The four acute porphyrias, namely ADP, AIP, HCP, and VP, are all hepatic. As shown in Table 17.20.1, effects on the nervous system occur in each of the acute porphyrias. Diagnosis is often delayed because the symptoms are nonspecific. AIP, HCP, and VP are autosomal

dominant inherited diseases, whereas ADP is autosomal recessive. At the molecular level, all show extensive allelic heterogeneity, with most mutations restricted to one or a few families. In some locations, founder effects have led to more common mutations; most notable are high prevalences of AIP in northern Sweden (Lee and Anvert, 1991), VP in South Africans of Dutch descent, and type 2 familial PCT in Norway (Meissner et al., 1996; Aarsand et al., 2009). Enzyme activities in AIP, HCP, and VP are reduced to ~50% of normal, indicating near or complete haploinsufficiency, and are much lower in ADP, in which both alleles are affected (Nordmann et al., 1997; Badminton and Elder, 2005). Many individuals who inherit AIP, HCP, and VP never have clinical manifestations. However, because porphyric attacks can be severe and life threatening, early diagnosis of carriers and affected individuals is important, so they can be educated to avoid factors that can trigger acute attacks, such as certain drugs, alcohol, and fasting (Anderson, 2003, 2014; also see <http://www.porphyrifoundation.com/testing-for-porphyrin>).

AIP, HCP, and VP are characterized by low clinical penetrance and environmental factors, and genes at other loci are probably important in increasing susceptibility to the development of clinical disease. Family studies in France (Puy et al., 2010) and the United Kingdom (UK; Badminton et al., 2014) suggest that about 10-20% of affected individuals develop symptoms, but figures as high as 50% have been reported for AIP from Sweden (Bylesjo et al., 2009). When minor skin lesions are taken into account, symptoms may develop in up to 40% of heterozygotes for VP mutations in South Africa (von und zu Fraunberg et al., 2002; Hift et al., 2004). Ascertainment bias may inflate these figures, as symptomatic individuals are more likely to be included in such analyses. No clear genotype-phenotype correlation has yet been established in any autosomal dominant porphyria, although there are reports that some mutations may be associated with higher penetrance (von und zu Fraunberg et al., 2002; Bylesjo et al., 2009).

AIP, HCP, and VP are characterized by episodic occurrence of life-threatening acute neurovisceral attacks, which are identical in all three conditions. In VP and HCP, bullous skin lesions may occur with or apart from acute attacks. Skin lesions are much more common in VP than in HCP. These occur in 10-50% of patients with VP, and may be the only clinical manifestation (Puy et al.,

2010). In the UK, ~60% of patients with VP present only with skin lesions that are identical to those of PCT (Whatley et al., 1999). Acute attacks are rare before puberty and often provoked by identifiable precipitants, notably certain drugs, endocrine factors, and alcohol. The management and prevention of porphyrias have recently been reviewed (Puy et al., 2010; Balwani and Desnick, 2012). Preventing acute attacks by advising patients to avoid porphyrogenic drugs (European Porphyria Network, <http://www.porphyrinetwork.org>) and other potential precipitants is an essential part of the management of families with AIP, HCP, or VP (Anderson et al., 2005).

Acute Intermittent Porphyria (AIP)

AIP (sometimes known as Swedish porphyria, pyrroloporphyria, or intermittent acute porphyria) is the most common of the acute porphyrias worldwide, with an estimated prevalence of ~5 per 100,000 in the United States, including individuals with latent porphyria. The disease was first described in 1889 by the Dutch physician Stokvis, who recognized that symptoms in his patient were precipitated by the barbiturate-related drug sulfonal (Stokvis, 1989). Waldenstrom noted a high prevalence of AIP in an area of northern Sweden, and found that it was inherited as an autosomal dominant trait (Waldenstrom, 1957; Tschudy et al., 1975).

AIP occurs in all races, but may be most common in northern European countries. In Europe (excluding Sweden), the incidence of newly diagnosed symptomatic individuals with AIP has been reported as 0.13 per million per year, with a calculated prevalence of 5.4 per one million (Elder et al., 2013). In Sweden, the incidence and prevalence of AIP were about four times higher than in other parts of Europe due to a founder effect centered in Lappland (Floderus et al., 2002). The UK may be another high incidence region, with a prevalence of hydroxymethylbilane synthase (HMBS) mutations as high as 1 per 500, with incomplete penetrance and an estimated prevalence of symptomatic disease of only 1-2 per 100,000 (Badminton and Elder, 2002). The estimated minimum prevalence of disease-specific HMBS mutations in France was 597 per million (Nordmann et al., 1997; Nordmann and Puy, 2002). The penetrance of overt AIP was recently reported in Europe as 5.4 per million (Whatley and Badminton, 2005, 2013; Badminton and Elder, 2002; Elder et al., 2013).

Clinical features of AIP

Most heterozygotes remain asymptomatic throughout life. Symptoms are very rare before puberty, and are more common in women than men (Whatley and Badminton, 2013). Symptoms are due to effects on the visceral, peripheral, autonomic, and central nervous systems. They usually occur as intermittent attacks that are sometimes life-threatening (Anderson et al., 2001, 2005; Herrick and McColl, 2005). The most common presentation is an attack of severe abdominal pain without peritoneal signs, often accompanied by nausea, vomiting, tachycardia, hypertension, anxiety, and agitation (Herrick and McColl, 2005; Pischik and Kauppinen, 2009). Dark or reddish urine may be observed. Central nervous system manifestations may progress to confusion, hallucinations, and seizures. The latter may be due to hyponatremia, resulting from hypothalamic involvement, and inappropriately high levels of antidiuretic hormone. Peripheral neuropathy causing pain and weakness can progress to quadriparesis and respiratory embarrassment. The skin is not ordinarily affected; however, concurrent advanced renal disease can limit porphyrin excretion and raise plasma porphyrin levels sufficiently to cause blistering lesions on sun-exposed skin. Early diagnosis is essential to avoid progression of attacks and to institute effective therapy (Herrick and McColl, 2005; Whatley and Badminton, 2013).

Factors that precipitate attacks include certain drugs, such as barbiturates, hydantoin, rifampicin and sulfonamide antibiotics, most of which are inducers of hepatic δ -aminolevulinic acid synthase (ALAS1) and cytochrome P450 enzymes (CYPs). Some women have attacks during the luteal phase of the cycle, when progesterone levels are increased. The reproductive steroids progesterone, medroxyprogesterone, and testosterone are particularly potent inducers of hepatic ALAS1 (Kappas et al., 1983; Thunell et al., 2007). Fasting and low-calorie diets can cause attacks due to ALAS induction, and this effect is mediated by peroxisome-proliferator-activated receptor- γ co-activator-1 (PGC-1 α ; Phillips and Kushner, 2005). Increased serum T4 and thyroxine binding globulin in the absence of hyperthyroidism, and elevated serum cholesterol and low-density lipoprotein, are sometimes seen.

Most people do not show symptoms of AIP attacks. Symptomatic AIP attacks, which are very rare before puberty, are more common in women than men (Whatley and Badminton,

2013). AIP manifests after puberty in women due to hormonal influences. Typically, women develop symptoms after puberty in their twenties, and men develop symptoms in their thirties. Attacks often result from a precipitating factor, which most likely induces ALAS1. Precipitating factors include drugs (especially barbiturates, sulfonamides, and hydantoin), hormonal changes, and fasting. Some women have cyclic menstrual attacks, during which progesterone increases heme catabolism, and synthetic estrogens and progesterones induce porphyria. Severe abdominal pain is the most common symptom, and other symptoms may include nausea, vomiting, constipation, muscle weakness, urinary retention, palpitation (due to rapid heart rate and often accompanied by hypertension), confusion, hallucinations, seizures, and pain in the back, arms, and legs. Symptoms develop over several hours or days. The skin is not affected (Chemmanur and Bonkovsky, 2004; Whatley and Badminton, 2013).

The most frequent presenting signs in patients with AIP are tachycardia, dark urine, confusion, and peripheral motor deficit. The white blood cell count may be elevated because of stress or infection. Other abnormalities include increased serum T4, thyroxine binding globulin (but AIP patients are usually euthyroid, only rarely frankly thyrotoxic), and elevated cholesterol and low-density lipoprotein levels, simulating an exaggerated estrogen effect.

Attacks may be complicated by neurologic findings (mental changes, convulsions, and peripheral neuropathy that may progress to respiratory paralysis) and hyponatremia. Acute attacks, which may be provoked by certain drugs, alcohol, endocrine factors, calorie restriction, stress, and infections, usually resolve within two weeks. Most individuals have one or a few attacks, but ~5% (mainly women) have recurrent attacks (defined as >4 attacks/year) that may persist for years. All individuals with a genetic change in the HMBS gene that predisposes to AIP are at risk of developing acute attacks; however, most never have symptoms (Badminton et al., 2012).

The major pathologic finding in AIP is muscle denervation. In patients with neuropathy, electromyographic (EMG) studies show a reduced motor nerve conduction velocity, and histopathology is consistent with axonal neuropathy and secondary demyelination. Brain histopathology at autopsy may show vacuolization of neurons and focal demyelination (Albers et al., 1978; Kuo et al., 2011).

AIP is associated with increased risk for HCC, chronic hypertension, and end-stage renal disease (Chemmanur and Bonkovsky, 2004; Badminton et al., 2012).

Etiology and pathogenesis of AIP

AIP develops in some individuals who are heterozygous for mutations of porphobilinogen deaminase (PBGD; also known as HMBS and formerly as uroporphyrinogen I synthase), the third enzyme in the heme biosynthetic pathway (Fig. 17.20.1). The half-normal enzyme activity found in all tissues results from the unaffected allele. PBGD catalyzes the assembly of four molecules of PBG to form HMB, a linear tetrapyrrole. PBGD has a unique cofactor, a dipyrrolomethane (i.e., a dipyrrole) that binds the pyrrole intermediates at the catalytic site until four additional pyrroles are assembled, forming a linear hexapyrrole, after which HMB is released (Jordan, 1990; Anderson et al., 2001). It is possible that high concentrations of PBG during exacerbations of acute porphyria may inhibit formation of the holo-deaminase and further reduce hepatic enzyme activity.

A 50% deficiency of PBGD is not sufficient by itself to cause AIP symptoms. Other activating factors that must also be present include certain steroid hormones, drugs, and dietary changes. During an AIP attack, the regulatory heme pool in the liver is depleted and there is marked induction of the housekeeping form of ALAS1, the rate-limiting enzyme for heme synthesis in the liver, leading to accumulation of ALA and PBG, the two intermediates proximal to the deficient enzyme.

At least 342 different HMBS mutations have been identified in AIP (Grandchamp et al., 1989; Di Pierro et al., 2006; Whatley et al., 2009; Barbaro et al., 2012; Human Gene Mutation Database [HGMD, <http://www.biobase-international.com/product/hgmd>]). All individuals with a genetic change in the HMBS gene that predisposes to AIP are at risk of developing acute attacks; however, most never have symptoms and are said to have latent (or presymptomatic) AIP (Chemmanur and Bonkovsky, 2004; Badminton et al., 2012).

Hereditary Coproporphyrria (HCP)

HCP is an inherited autosomal dominant and a rare recessive form of hepatic porphyria and is less common than AIP, though latent HCP and HCP carriers are being increasingly recognized. The prevalence of HCP in Den-

mark is ~2 per million. HCP is the least prevalent of the three principal types of acute porphyria: AIP, HCP, and VP. Symptoms in HCP may be less frequent than in AIP or VP. Environmental or physiologic factors play a role in the pathogenesis of acute attack (Badminton and Elder, 2005).

Clinical features of HCP

HCP is an acute hepatic porphyria with neurovisceral symptoms, usually occurring as attacks that are indistinguishable from those in AIP (Bissell et al., 2012). Attacks typically start with low-grade abdominal pain that slowly increases over a period of hours or days, often with nausea and vomiting. Sometimes pain is predominantly in the back or extremities. If untreated, a motor neuropathy may develop over a period of days or weeks. The neuropathy and weakness is often first noted proximally in the arms and legs, and may then progress distally. Respiratory insufficiency may result from impaired innervation of the diaphragm and respiratory muscles. Acute attacks are often associated with use of certain medications, caloric deprivation, and luteal-phase increases in progesterone. About 20% of those with an acute attack report photosensitivity, although bullae and skin fragility are much less common than in VP (Anderson et al., 2005; Anderson, 2014; also see <http://www.porphyrifoundation.com/testing-for-porphyrria>). Of 46 individuals tested in Germany with acute HCP, 90% had abdominal pain; only 13% had cutaneous findings despite substantial overproduction of coproporphyrin (Kühnel et al., 2000). An earlier British study of 111 individuals with HCP reported similar findings (Brodie et al., 1977).

Although disease-causing mutations in coproporphyrinogen oxidase (CPOX) occur equally in males and females, acute attacks are much more frequent in women, mainly between ages 16 and 45 years (the years of active ovulation). Chronic cutaneous HCP is suspected in individuals with bullae and fragility of light-exposed skin that result in depigmented scars; however, cutaneous signs occur in only a minority of heterozygotes, even during an acute attack. In general, HCP is milder than AIP and is associated with fewer attacks. For example, in 32 members of an Australian family, 14 (including 10 adults) were determined to have HCP on the basis of a high fecal coproporphyrin III/I ratio and/or low lymphocyte CPOX enzyme activity, but only one had clinical symptoms of porphyria (Blake et al., 1992).

In rare homozygous cases of HCP, a CPOX mutation is inherited from each parent, with at least one of the mutant alleles expressing some enzyme activity. Characteristically, photosensitivity and chronic neurological manifestations begin in childhood, but acute attacks are seldom described (Schmitt et al., 2005).

Etiology and pathogenesis of HCP

Like AIP and VP, HCP is inherited in an autosomal dominant manner with low penetrance. Heme production in most heterozygotes appears to be adequate. HCP results from CPOX deficiency. At least 64 CPOX gene mutations involving all seven exons have been identified in different HCP families, including missense and nonsense mutations, large and small deletions and insertions, and splice site mutations (Rosipal et al., 1999; Schmitt et al., 2005; HGMD, <http://www.biobase-international.com/product/hgmd>), as well as a few large deletions (Whatley et al., 2009; Barbaro et al., 2012). The enzyme functions as a homodimer, and some CPOX mutations may disrupt dimer formation (Lee et al., 2005). Homozygous cases of HCP have more severe CPOX deficiency, with onset of the disease in childhood.

CPOX catalyzes the two-step decarboxylation of coproporphyrinogen III to protoporphyrinogen IX. Certain CPOX mutations release the substrate after one decarboxylation as harderoporphyrinogen, a tricarboxylate porphyrinogen that is then oxidized to the corresponding porphyrin. Homozygotes for these mutations have some distinct features, such as hemolysis early in life, whereas heterozygotes are similar to other HCP patients.

Because of reduced penetrance, many individuals with a CPOX mutation have no signs or symptoms of HCP. Given the rarity of acute attacks of HCP relative to AIP, it is suspected that only a small minority of CPOX heterozygotes express the clinical disease.

Variegate Porphyria (VP)

This disease is termed variegate because of its varied symptoms, which can include severe neurovisceral symptoms or chronic blistering skin lesions that are identical to those seen in PCT (Eales et al., 1980; Kirsch et al., 1998; Meissner et al., 2003). VP has also been referred to as porphyria variegata, South African genetic porphyria, mixed porphyria, protocoproporphyria, and porphyria cutanea tarda hereditaria (Kirsch et al., 1998; Meissner et al., 2003).

VP is an autosomal dominant genetic disorder due to partially deficient activity of the mitochondrial enzyme protoporphyrinogen oxidase (PPOX; Brenner and Bloomer, 1980; Singal and Anderson, 2013). Enzyme activity is ~50% of normal in all tissues and mitochondria-containing cells examined, including lymphocytes and cultured fibroblasts (Meissner et al., 2003). Speculation that King George III of England and others in the royal family had VP (Macalpine and Hunter, 1966) has been discounted (Peters, 2009).

VP occurs worldwide, but its prevalence is not accurately known because many carriers of PPOX mutations remain asymptomatic. The prevalence of VP is 1 in 300 among the white South African population of Dutch descent, due to a founder effect (Eales et al., 1980; Meissner et al., 1996, 2012; Hift et al., 1997). A particular PPOX missense mutation (R59W) is highly prevalent in this population (Meissner et al., 1996). Lower prevalences of VP have been estimated in Finland (1.3 per 100,000; Mustajoki, 1980) and Europe in general (0.3 per 100,000; Elder, 1997).

Clinical features of VP

The clinical presentation of VP is variable in nature and hence its name. Clinical manifestations are more common in women than in men. VP can cause acute attacks identical to those in AIP, with abdominal pain, vomiting, constipation, hypertension, tachycardia, and neuromuscular weakness that can progress to quadriplegia and respiratory weakness (Chemmanur and Bonkovsky, 2004). Phototoxic manifestations may include bullae, erosions, or ulcers after mild trauma, as in PCT.

The most common manifestation of VP is adult-onset cutaneous blistering lesions (subepidermal vesicles, bullae, and erosions that crust over and heal slowly) of sun-exposed skin, especially the hands and face. Other chronic skin findings include milia, scarring, thickening, and areas of decreased and increased pigmentation. Facial hyperpigmentation and hypertrichosis may occur.

Acute neurovisceral symptoms can occur any time after puberty and are highly variable, but may be similar from episode to episode in a patient with recurrent attacks. Symptoms may become chronic. The most common manifestations are abdominal pain, constipation, tachycardia, hypertension, pain in the back, chest, and extremities, anxiety, agitation, seizures, and neuromuscular weakness that may progress to quadriparesis and

respiratory paralysis (Singhal and Anderson, 2013).

Very rare homozygous cases of VP, in which a PPOX mutation is inherited from each parent, manifest cutaneous photosensitivity and severe neurological manifestations beginning in childhood. At least one of the mutant alleles in the homozygous disease must express some enzyme activity. Interestingly, acute attacks are seldom described in homozygous cases (Frank et al., 1998; Kauppinen et al., 2001).

The diagnosis of VP is established by biochemical testing and confirmed by identification of a heterozygous mutation in PPOX (Singhal and Anderson, 2013). Acute attacks are managed and prevented as in AIP (Anderson et al., 2005; also see <http://www.porphyrifoundation.com/testing-for-porphyrria>). Treatment of acute attacks is the same as in AIP. No effective treatment for the skin is available, other than avoiding sunlight. It is important to distinguish VP or HCP from PCT, because treatment that is successful in PCT (phlebotomy or low-dose hydroxychloroquine) is not helpful in VP and HCP.

Etiology and pathogenesis of VP

The PPOX gene contains 13 exons and is localized to chromosome 1 (Roberts et al., 1995). VP is genetically heterogeneous, with more than 140 different mutations identified (Whatley et al., 1999; Meissner et al., 2003). In South Africa, ~95% of cases are due to the R59W missense mutation, due to a well described founder effect (Meissner et al., 1996; Warnich et al., 1996). PPOX mutations in VP generally express little or no enzymatic activity. Accordingly, residual enzyme activity is due to the normal allele that is in trans to the mutant allele. Although some mutations are reported to cause a milder phenotype (von und zu Fraunberg et al., 2002), genotype-phenotype correlations are less evident in larger studies (Whatley et al., 1999).

The combined use of restriction enzyme and single-strand conformation polymorphism analysis allows a rapid and accurate diagnosis of VP in South Africa. The R59W mutation was shown to be associated with one of four potential haplotypes defined by two polymorphisms in exon 1 of the PPOX gene, which supports the founder hypothesis for VP in South Africa (Warnich et al., 1996). The diagnosis of VP is established by biochemical testing and confirmed by identification of a heterozygous mutation in the PPOX gene (Singhal and Anderson, 2013).

δ-Aminolevulinic Acid Dehydratase Deficiency Porphyria (ADP)

ADP, also referred to as Doss porphyria after the investigator who described the first two cases and subsequently a third, results from a profound deficiency of δ-aminolevulinic acid dehydratase (ALAD; also known as PBG synthase), the second enzyme in the heme biosynthetic pathway (Doss and Schmidt, 1972). ADP is the rarest type of porphyria, with only six documented cases reported worldwide (Sassa, 1998; Akagi et al., 2006; Balwani and Desnick, 2012). It is an acute porphyria and is an autosomal recessive disorder. Patients are usually compound heterozygotes for ALAD mutations. Heterozygotes may be more susceptible to toxicity from lead, which inhibits this enzyme by displacing zinc (Scinicariello et al., 2007).

Clinical features of ADP

Patients with ADP have neurovisceral symptoms, as in other acute porphyrias, and no cutaneous manifestations. Heterozygous subjects have ~50% of normal ALAD activity and are clinically asymptomatic (Bird et al., 1979). All six cases documented to date have been males, four of whom experienced onset of symptoms at about 14 years of age. Another patient was a child with neurological impairment from birth, and the sixth experienced adult onset associated with a myeloproliferative disorder (Sassa, 1998; Maruno et al., 2001; Doss et al., 2004). Treatment with hemin was effective in the four young males, but glucose loading was not. ADP is assumed to be a hepatic porphyria, although liver transplantation was not beneficial in the child with severe disease.

In addition to decreased activity due to an inherited genetic defect, ALAD can be inhibited under a number of circumstances. The differential diagnosis of ADP should include other hepatic porphyrias (AIP, HCP, and VP) and toxic states in which ALAD activity is suppressed, which include lead poisoning, hereditary tyrosinemia, zinc deficiency, smoking, alcoholism, diabetes mellitus, and chronic renal insufficiency. ALAD activity is reduced in diabetes mellitus (Fernández-Cuartero et al., 1999) patients, in dialysis patients with chronic liver failure (Guolo et al., 1996), and in smokers and alcoholics (McCull et al., 1981). ADP must also be differentiated from other causes of ALAD deficiency, such as lead poisoning and hereditary tyrosinemia type 1, which can cause increases in ALA, coproporphyrin III, and erythrocyte

protoporphyrin, with symptoms very much like those in acute porphyrias. Lead metal inhibits ALAD activity by displacing zinc from the enzyme (Granick et al., 1978; Bergdahl et al., 1997), and thus individuals with heterozygous ALAD deficiency may be more susceptible to lead poisoning (Doss et al., 1984). Succinylacetone, a structural analog of ALA and a potent inhibitor of ALAD (Sassa and Kappas, 1983), is increased in plasma and urine of patients with hereditary tyrosinemia type 1 (Lindblad et al., 1977). It has been estimated that ~40% of children with hereditary tyrosinemia type 1 develop the signs and symptoms of ADP (Rank et al., 1991). ALAD activity is reduced in rats exposed to trichloroethylene (Fujita et al., 1984), styrene (Fujita et al., 1986), lead (Sassa et al., 1975), and iron (Bonkovsky et al., 1987).

Etiology and pathogenesis of ADP

ALAD catalyzes the formation of the monopyrrole PBG from two molecules of ALA, a precursor committed to synthesis of porphyrins, heme, and other tetrapyrroles. Human ALAD is a homo-octamer with a subunit size of 36,274 Da (Wetmur et al., 1986), and is encoded by the ALAD gene localized at chromosome 9q34 (Potluri et al., 1987). There are two common alleles for ALAD, encoding either lysine or asparagine at residue 59 (Wetmur et al., 1991). The relative frequencies of these alleles vary among populations (Jaffe and Stith, 2007). The enzyme requires an intact sulfhydryl group and one zinc atom (Zn^{2+}) per subunit for full activity (Sassa, 1982). ALAD is present in vast abundance in mammalian cells. In liver, ALAD activity is 80- to 100-fold greater than that of ALAS, the first and rate-limiting enzyme for hepatic heme biosynthesis (Kappas et al., 1995). The normal abundance of this enzyme explains why heterozygotes with ~50% of normal ALAD activity are asymptomatic.

Based on an analysis of a small population, it has been estimated that the prevalence of individuals with 50% of normal ALAD activity, putatively caused by one aberrant ALAD allele, is 2% in the normal asymptomatic population (Thunell et al., 1987). This study suggested that most instances of compound heterozygosity in ALAD result in spontaneous abortions. The frequency of genetic carriers for ALAD deficiency (i.e., heterozygotes) in the normal population in Sweden was estimated to be ~2%. Although subjects with heterozygosity for ALAD deficiency are asymptomatic, they may be considered to be at risk for de-

veloping ADP when exposed to environmental chemicals or toxins, which further inhibit ALAD activity (Thunell et al., 1987).

ALAD is markedly deficient and ALA substantially elevated in plasma and urine in patients with ADP. ALA is further metabolized to other heme precursors, and as a result coproporphyrin III is excreted in urine in large amounts and protoporphyrin IX is increased in erythrocytes. As in other acute porphyrias, the mechanism of neurological damage is not well understood.

NON-ACUTE HEPATIC PORPHYRIAS

PCT is a hepatic porphyria that causes chronic blistering skin phototoxicity, but has no neurological manifestations, making it distinct from the acute hepatic porphyrias discussed above. HEP is usually a more severe disease and is the homozygous form of familial PCT. Both PCT and HEP are due to deficient activity of hepatic uroporphyrinogen decarboxylase (UROD), the fifth enzyme in the heme biosynthetic pathway. Two of the acute porphyrias (HCP and VP), as well as mild cases of HEP and CEP (discussed below), can present with skin lesions identical to those of PCT. Because PCT is the most common porphyria, it is important to differentiate it from these less common porphyrias so that appropriate management can be offered.

Porphyria cutanea tarda (PCT)

PCT is universal and the most common porphyria, frequently seen in clinical practice. The prevalence of PCT varies worldwide, ~1 in 10,000 in the general population (Frank and Poblete-Gutierrez, 2010; Badminton et al., 2014). The incidence of PCT in the UK was estimated to be 2 to 5 per million (Elder, 1998; Bleasel and Varigos, 2000; Sarkany, 2001). A registry has been established by the NIH-funded Porphyrias Consortium (<http://rarediseasesnetwork.epi.usf.edu/registry/direct.htm>) to more accurately enumerate cases of various types of porphyrias occurring in the U.S. population. The disease occurs in both sexes, but is somewhat more common in men, with onset usually during the fifth and sixth decades.

Clinical features of PCT

Patients usually present with skin fragility and bullae on sun-exposed skin, most commonly on the backs of the hands (Elder, 1990; Frank and Poblete-Gutierrez, 2010). Evidence of liver dysfunction is common, and amounts of iron in the liver are normal or increased.

Risk of developing HCC is increased in PCT (Francanzani et al., 2001), and is often related in part to one or more liver-damaging susceptibility factors being greater than normal (Bonkovsky et al., 1998; Frank and Poblete-Gutierrez, 2010).

PCT is the only porphyria that can develop in the absence of an inherited mutation of the affected enzyme. Only ~20% of patients with this condition have a heterozygous UROD mutation, which lowers UROD activity in all tissues to ~50% of normal. These mutations increase susceptibility to develop PCT, but acquisition of additional susceptibility factors are needed to reduce the hepatic enzyme activity to less than ~20% of normal and cause porphyrin accumulation. Therefore, PCT is primarily an acquired disorder in which behavioral, environmental, infectious, and genetic factors interact to cause a substantial deficiency of hepatic UROD activity.

PCT is caused by the partial deficiency of UROD enzyme activity, inherited or acquired, with resultant accumulation of uroporphyrin and 7-carboxyl porphyrinogen, mostly in the liver (Elder and Roberts, 1995). The disease usually appears in middle-aged individuals, the majority of them over 40 years old (Siersema et al., 1995). In the past, it was found mostly in men, but the incidence in women has been increasing due to increasing intake of estrogens and alcohol consumption (Grossman et al., 1979; Bygum et al., 2003; Singal and Phillips, 2014). The presence of different levels of UROD activity in PCT patients has promoted its subdivision (Kushner et al., 1976) into the following four types.

Type 1 or sporadic PCT (s-PCT) is symptomatic or acquired. It encompasses 72% to 84% of cases (Held et al., 1989; Elder, 1998; Elder and Worwood, 1998). There is no family history in type 1 PCT. The enzyme deficiency is restricted to the liver, and there is normal erythrocyte UROD activity (Elder et al., 1985). The specific enzyme defect is not caused by mutation in the UROD locus (Elder and Roberts, 1995), and cDNA sequences of hepatic and extra-hepatic UROD, as well as the promoter region of the gene, are normal (Garey et al., 1993).

Type 2 or familial PCT is inherited. It comprises 16% to 28% of cases. UROD activity is reduced to half normal in all tissues (erythrocytes and liver) due to reduction in enzyme synthesis or stability (Verneuil et al., 1978; Held et al., 1989; Elder, 1998; Thunell and Harper, 2000). Differentiation between PCT types 1 and 2 cannot be based solely on ery-

throcyte UROD activity, which may be at the lower limit in type 2 and below the normal interval in type 1 (Held et al., 1989; Doss et al., 1991). DNA testing is preferred for identification of familial cases (Bygum et al., 2003). Mutations in the UROD gene discriminate familial from sporadic forms. Many UROD mutations (>40) in the 1p34 chromosome diminish enzyme stability or cause altered pre-RNA splicing (Thunell and Harper, 2000; Bygum et al., 2003). Most individuals who inherit the enzyme defect do not manifest the disorder, suggesting that additional genetic or non-genetic factors are needed for the disease to be expressed (Thunell and Harper, 2000). The age at onset, severity of symptoms, sex distribution, and liver enzyme and iron profiles of type 2 are not different from type 1 (Bygum et al., 2003).

Type 3 PCT is biochemically indistinguishable from type 1 (with normal erythrocyte UROD levels), but it affects more than one family member (D'Alessandro Gondolfo et al., 1989). It occurs in a small number of patients (<5%). The promoter region and the coding UROD DNA sequence are normal, suggesting that other loci are involved, and these may be genes affecting tissue iron (Held et al., 1989; Garey et al., 1993). It is not proven that PCT type 1 is a distinct form of the disease, or this would be PCT type 1 with an inherited contribution (Elder, 1998).

Toxic PCT (not called as type 4) occurs after exposure to toxic chemicals such as hexachlorobenzene (Cripps et al., 1984) and 2,3,7,8-tetrachlorodibenzo-*p*-dioxin (TCDD), which diminish hepatic UROD activity (Pazderova-Vejlupková et al., 1981).

PCT is an iron-related disorder — another feature that is different from other porphyrias. The disease always occurs with a normal or increased amount of hepatic iron, iron deficiency is protective, and the prevalence of hemochromatosis (HFE) mutations is increased. Repeated phlebotomy to reduce hepatic iron is an effective treatment, and iron administration can lead to recurrence of the disease.

Multiple readily identified susceptibility factors are found in individual patients, but none is found in all (i.e., none is required for PCT to develop). These factors include alcohol (87%), smoking (81%), hepatitis C (69%), HIV infection (13%), estrogen (66% in females), HFE mutations (53%), and UROD mutations (17%) (numbers in parentheses indicate frequencies in one large US series; Jalil et al., 2010). HFE mutations, alcohol, and hepatitis C are known to decrease hepcidin levels

and thereby increase iron absorption from the intestine. A number of these factors also increase oxidative stress and CYPs in hepatocytes.

PCT can develop from and be reproduced in laboratory animals by exposure to certain halogenated chemicals. In the late 1950s, over 3000 people in Turkey developed toxic PCT from ingestion of the fungicide hexachlorobenzene, used to preserve wheat intended for planting (Schmid, 1960; Cam and Nigogosyan, 1963; Cripps et al., 1984). Smaller outbreaks of PCT from industrial exposures of other polyhalogenated hydrocarbons such as dioxins and triazine herbicides have been observed (Bleiberg et al., 1964; Oliver, 1975). Such exposures are rarely evident in sporadically occurring cases of PCT seen in clinical practice.

Etiology and pathogenesis of PCT

PCT results from inhibition of UROD in the liver. UROD is a cytosolic enzyme that catalyzes the sequential decarboxylation of the four acetic acid substituents of uroporphyrinogen to the four methyl groups of coproporphyrinogen. A single gene, mapped to chromosome 1p34, encodes UROD (Verneuil et al., 1984b, 1986). UROD is a 41-kDa polypeptide cytosolic enzyme that has no tissue-specific isoenzymes (Roméo et al., 1986). A porphomethene inhibitor of UROD has been identified in genetically engineered mice with homozygous HFE mutations and a heterozygous UROD mutation. The inhibitor is the product of oxidation of one of the four methene bridges of uroporphyrinogen. The oxidative process involves CYPs and requires ferrous iron (Phillips et al., 2007a).

Decreased UROD activity leads to three types of hepatic porphyria, namely types 1 and 2 PCT and HEP (Kappas et al., 1995; Touart and Sau, 1998). Decreased UROD leads to increased production of 8- to 5-carboxymethyl-substituted porphyrinogens (De Matteis, 1998). These compounds auto-oxidize to porphyrins, which accumulate in the liver in large amounts, and are transported in plasma to the skin, where they act as photosensitizers, and excreted in urine and bile (De Matteis, 1998). Excess porphyrins in the skin interact with light of approximately 400-nm wavelength, and are activated and generate reactive oxygen species that cause skin damage and increased fragility (Grossman and Poh-Fitzpatrick, 1980; Lim, 1989).

The livers of patients with PCT contain high concentrations of uroporphyrins and heptacarboxyl porphyrins. Most PCT patients

have increased ferritin, serum iron, and iron-binding saturation, suggesting that iron plays an important role in the pathogenesis of PCT. Liver function abnormalities are common but are usually mild, although they sometimes progress to cirrhosis and even liver cancer (Frank and Poblete-Gutierrez, 2010). The incidence of HCC in PCT is greater than normal. PCT is often associated with hepatitis C infection, which can also cause these liver complications. However, liver tests are generally abnormal even in PCT patients without hepatitis C infection (Bonkovsky et al., 1998; Frank and Poblete-Gutierrez, 2010).

Iron plays a role in the pathogenesis of PCT, although the exact mechanism is unclear. Mild to moderate systemic or liver iron overload is present in the majority of patients (Sampietro et al., 1999). Over 80% of PCT patients have hepatic siderosis and elevated plasma ferritin (Grossman et al., 1979; Rocchi et al., 1986; Elder and Roberts, 1995; Siersema et al., 1995). Iron removal returns UROD activity to normal in type 1 PCT (Sweeney, 1986; Elder et al., 1989). Administration of iron accelerates the onset of PCT and produces relapse in phlebotomy-induced remissions (Lundvall, 1971; Felsher et al., 1973). However, since PCT is uncommon in hereditary hemochromatosis, iron is not thought to be the sole etiological agent. Iron may increase production of peroxides and free radicals, leading to oxidation of uroporphyrinogen in the cell, direct liver damage, production of an inhibitor of UROD or direct modification of the enzyme itself (Mukerji et al., 1984; Bonkovsky, 1989; De Matteis, 1998).

An association has been found between PCT and the hemochromatosis gene mutation C282Y (Fodinger and Sunder-Plassmann, 1999; Mehrany et al., 2004; Bovenschen and Vissers, 2009). This mutation has been found in ~44% of patients with type 1 PCT in the UK (Roberts et al., 1997), the Netherlands (Santos et al., 1997) and Australia (Stuart et al., 1998). An increase in the H63D mutation, but not the C282Y mutation, was found in Italy (Sampietro et al., 1998). In this population, the frequency of the C282Y mutation was lower, and the incidence of hepatitis C virus (HCV) was higher. These observations have led to the hypothesis that the C282Y mutation may trigger PCT independently of viral disease by promoting the accumulation of iron, whereas HCV and H63D may synergize to produce clinically manifested PCT (Elder and Worwood, 1998; Sampietro et al., 1998). Hence, inheritance of the C282Y mutation may contribute to

the genetic susceptibility for PCT, precipitating PCT in predisposed individuals (Fodinger and Sunder-Plassmann, 1999).

Over 108 UROD mutations have been identified in patients with familial type 2 PCT and in HEP (Elder et al., 1981; Moran-Jimenez et al., 1996; Elder, 1998; Mendez et al., 1998). Erythrocyte UROD activity is ~50% of normal in type 2 PCT, but other factors such as increased erythropoiesis can increase UROD activity. Therefore, UROD gene sequencing has greater diagnostic accuracy for identifying those with UROD mutations (Aarsand et al., 2009; Badenas et al., 2009). Identifying a UROD mutation is part of the complete evaluation of patients for susceptibility factors, and may account for earlier-than-usual onset of the disease.

Mutational analysis of UROD may not be needed for the diagnosis of PCT except in rare instances when HEP is suspected (Moran-Jimenez et al., 1996). There is a debate about whether all patients with PCT should be offered testing to identify those with type 2 PCT (Sarkany, 2008; Aarsand et al., 2009; Puy et al., 2010). However, mutational analysis of UROD has greater diagnostic accuracy than measurement of erythrocyte UROD activity for this purpose (Aarsand et al., 2009; Badenas et al., 2009).

PCT is the most readily treated form of porphyria. Phlebotomies to deplete iron, guided by estimating the serum ferritin level, can be used to treat PCT. Low-dose hydroxychloroquine, which removes excess porphyrins from the liver, is also highly effective. Hydroxychloroquine (and chloroquine) in amounts used for other diseases cause hepatotoxicity in PCT, but this adverse effect is largely avoided with the low-dose regimen. Time to remission is approximately the same with these treatments (Singal et al., 2012).

Differentiation of type 2 versus type 1 PCT has no benefit for the individual patient, because the response to treatment and prognosis of the two forms is similar. DNA results do not influence treatment, since all PCT types respond to phlebotomy or low-dose hydroxychloroquine. Screening of type 2 PCT families does allow mutation carriers to be counseled about the need to avoid other susceptibility factors (Sarkany, 2008; Whatley and Badminton, 2013).

Risk and other associated precipitating factors for PCT

The major risk factors of PCT are excess alcohol intake, cigarette smoking, increased

iron (iron overload or hemochromatosis), certain chronic viral infections (especially HCV and HIV), and estrogens. One or more of these precipitating factors can be found in over 80% of patients with PCT (Grossman et al., 1979; Elder, 1998; Egger et al., 2002; Gisbert et al., 2003). Genetic predisposition seems to be an important factor, as only a small proportion of people exposed to alcohol and estrogens develop PCT (De Matteis, 1998). About 20% to 25% of persons with PCT also have a genetic predisposition in the form of an inherited partial deficiency of UROD enzyme. However, such a deficiency in itself is not sufficient to produce symptomatic PCT; other factors are also needed (Anderson, 2003; also see <http://www.porphyrifoundation.com/testing-for-porphyrin>).

There are several suggested mechanisms for the role of alcohol in PCT. Alcohol increases iron absorption resulting in iron accumulation in the liver, stimulates hepatic ALAS enzyme and free radical production, and is independently hepatotoxic (Grossman and Poh-Fitzpatrick, 1980; De Matteis, 1998). Alcohol induces hepatic ALAS1 and erythrocyte UROD activity in PCT patients. Alcohol also inhibits other enzymes in the heme pathway, and chronic alcoholism suppresses erythropoiesis and increases dietary iron absorption. Large amounts of porphyrins build up in the liver when the disease is becoming active. The disease becomes active when acquired factors—such as iron, alcohol, HCV, HIV, estrogens (for example, used in oral contraceptives and prostate cancer treatment), and possibly smoking—combine to cause a UROD deficiency in the liver. Hemochromatosis, an iron overload disorder, can also predispose individuals to PCT (De Matteis, 1998; Egger et al., 2002; also see <http://www.porphyrifoundation.com/testing-for-porphyrin>).

PCT, hepatitis C virus, and human immunodeficiency virus

HCV and HIV infections have been shown to be associated with PCT (Tsukazaki et al., 1998; Gisbert et al., 2003). The role of HCV in PCT is not well understood, and several studies have indicated that HCV alone is insufficient to cause PCT (Cribier et al., 1996, 2009; O'Reilly et al., 1996; Gomi et al., 1997; Bonkovsky et al., 1998). A possible hypothesis was that HCV triggers symptomatic PCT in genetically predisposed individuals (Pawlotzky et al., 1995; Dabrowska et al., 1998;

Lamoril et al., 1998; Moran et al., 1998; Chuang et al., 1999; Chiaverini et al., 2003).

The HIV infection is associated with altered porphyrin metabolism and appears to be an independent risk factor for PCT. Several mechanisms have been proposed for the role of HIV in the development of PCT, including direct hepatic damage by HIV (Mansourati et al., 1999), altered porphyrin biosynthesis (Boisseau et al., 1991; Sepkowitz et al., 1995), and impairment of the cytochrome P450 mixed-function oxidase system (Wissel et al., 1987; McAlister et al., 1995). The combination of HCV and HIV seems to be more potent than either virus alone in causing abnormalities in porphyrin metabolism (Blauvelt, 1996; O'Connor et al., 1996).

Hepatoerythropoietic Porphyrria (HEP)

HEP is a rare form of cutaneous porphyria (Romeo and Levin, 1969), with ~40 cases reported up to 2010 (Cantatore-Francis et al., 2010). HEP is a homozygous or compound heterozygous form of type 2 PCT, and results from a severe UROD deficiency (Deybach et al., 1981; Elder et al., 1981; Verneuil et al., 1984b, 1986; Smith, 1986; Meguro et al., 1994; Elder, 1997; Fritsch et al., 1997; Cantatore-Francis et al., 2010). The disease occurs worldwide and in both males and females. It is inherited as an autosomal recessive trait.

Clinical features of HEP

Clinical manifestations usually develop during infancy or early childhood and include extreme photosensitivity, skin fragility (bullae, erosions, and scarring) in sun-exposed areas, hypertrichosis, erythrodontia, and pink to red urine. Sclerodermoid skin changes often become evident over time. Compared to PCT, the cutaneous features of HEP typically have earlier onset, increased severity leading to disfigurement, and closer resemblance to those in CEP (Gunther's disease). Extracutaneous findings, including hemolytic anemia, are more frequent and severe in CEP than in HEP.

Cutaneous photosensitivity usually begins in early childhood and is usually more severe than in PCT, and resembles CEP (Elder et al., 1981; Lim and Poh-Fitzpatrick, 1984). Bacterial infection, scarring, and photomutilation can occur. Mild and nonspecific abnormalities in liver function and histology are common, usually without siderosis (Desnick and Astrin, 2002; Anderson, 2003; also see [*for-porphyrria*\). Developmental delay and seizures have been reported in HEP. A 4-year-old boy had delayed speech and language skills, then presented with focal seizures and acute left hemiparesis \(Parsons et al., 1994\).](http://www.porphyrifoundation.com/testing-</p></div><div data-bbox=)

Hemolytic anemia is less frequent and severe than in CEP, but anemia due at least in part to hemolysis is common and may be accompanied by hepatosplenomegaly (Meguro et al., 1994; Elder, 2003). Anemia was present in >50% of HEP patients for whom hematologic status was reported (15/27), but severe anemia requiring transfusions or administration of epoetin- α has only been observed in a few individuals (Horina and Wolf, 2000; Armstrong et al., 2004; Phillips et al., 2007c; Remenyik et al., 2008). Some patients present with hemolytic anemia and splenomegaly. Hematological abnormalities may include mild, normocytic, and normochromic anemia due in part to hemolysis.

HEP is clinically manifest by the onset of photosensitivity, scarring of sun-exposed skin, and hypertrichosis within the first few years of life (Elder et al., 1981; Lim and Poh-Fitzpatrick, 1984). Clinical features in milder and later-onset cases may be indistinguishable from PCT. Most patients with HEP develop photosensitive eruptions during infancy or early childhood. Spontaneous improvement of acute photosensitivity during later childhood with persistent skin fragility has been described. Some patients have presented in the second or third decade of life with mild skin fragility or photodistributed annular plaques. Photomutilation can result in considerable morbidity in patients with HEP via impaired function of the hands and facial disfigurement, making photoprotection essential. Sclerodactyly, osteolysis, and shortening of the phalanges, as well as progressive joint deformities, can occur as components of acral photomutilation in patients with HEP, CEP, and homozygous VP. Bacterial infections and scarring with disfiguration can occur. Sun-induced erythema and blistering occurred by age 2 years in 75% of reported cases. Sclerodermoid skin changes may be prominent.

Onset in adulthood has been reported (Moran-Jimenez et al., 1996; Horina and Wolf, 2000), and such cases may be misdiagnosed as PCT. Two young adults (ages 21 and 23) with severe HEP developed generalized seizures and had neuroimaging evidence of cerebral cortical atrophy and calcifications in the frontal lobes, presumably related to hypoxic injury, as in other porphyrias (Berenguer et al., 1997).

Biochemical abnormalities resemble PCT, but with substantially elevated levels of erythrocyte protoporphyrin (predominantly zinc protoporphyrin). Thus, molecular mutational analysis to identify both mutations is indicated for the diagnosis of HEP (Phillips et al., 2007c).

Etiology and pathogenesis of HEP

UROD activity is usually 10% or less than normal when measured in erythrocytes of patients with HEP (Gunther, 1967; Elder et al., 1981; Day and Strauss, 1982; Lazaro et al., 1984; Verneuil et al., 1984a,b; Fujita et al., 1987; Koszo et al., 1990; Meguro et al., 1994; Elder, 2003; Sassa, 2006; Cantatore-Francis et al., 2010). The marked reduction of UROD enzyme activity in HEP leads to accumulation of highly carboxylated porphyrinogens and porphyrins in liver and possibly other tissues. HEP is primarily hepatic, although a marked increase in erythrocyte zinc protoporphyrin indicates that the heme biosynthetic pathway in the bone marrow is also affected. The excess zinc protoporphyrin in erythrocytes is probably formed from pathway intermediates that accumulate during hemoglobin synthesis and are later metabolized to protoporphyrin, and then complexed with zinc (Phillips et al., 2007c). HEP is the recessive form of type 2 PCT, an autosomal dominant condition in which heterozygous UROD mutations predispose carriers to clinical manifestations (Verneuil et al., 1984a,b).

Patients are either homozygous or compound heterozygous for UROD mutations, and at least one allele must express some UROD enzymatic activity, since a null mutation would be lethal in the homozygous state (Elder et al., 1981; Verneuil et al., 1984a,b). Thus, null mutations are much less common in HEP than in heterozygotes with type 2 PCT (Phillips et al., 2007c).

Over 40 UROD mutations have been described, with some occurring in both HEP and familial PCT. Fifteen missense mutations, two deletions, and one nonsense mutation have been reported in HEP (Phillips et al., 2007c; Granata et al., 2009). The hepatic UROD inhibitor and susceptibility factors that are important in PCT generally do not have a significant role in HEP (Phillips et al., 2007c; Granata et al., 2009).

Severe cutaneous findings, an HFE H63D mutation, and elevated ferritin levels were described in a 2-year-old boy with HEP (Phillips et al., 2007c). Although HEP is considered a homozygous form of type 2 PCT, only one of

the ten mutations identified in HEP has been shown to be associated with PCT (Garey et al., 1990; Meguro et al., 1994; Roberts et al., 1995; McManus et al., 1996; Moran-Jimenez et al., 1996).

ERYTHROPOIETIC PORPHYRIAS

There are three erythropoietic types of porphyria. CEP is rare, with skin manifestations that resemble PCT, but are usually much more severe. EPP is the most common porphyria in children, and on average is perhaps associated with the longest delay in diagnosis. XLP is less common and has the same phenotype as EPP, and therefore these are described together.

Congenital Erythropoietic Porphyria (CEP)

CEP (also known as Gunther's disease) is a very rare autosomal recessive disease, characterized by blistering cutaneous photosensitivity (Gunther, 1967). CEP is estimated to affect ~3 per 10 million in the UK (European Porphyria Network, <http://www.porphyrria-europe.org>). Affected individuals are homozygous or compound heterozygous for uroporphyrinogen synthase (UROS) mutations. In one case the disease was due to mutations in the gene encoding the transcriptional regulator GATA1 (Phillips et al., 2007b,c; Puy et al., 2010; Campbell et al., 2013; Whatley and Badminton, 2013).

Clinical features of CEP

The phenotype can vary depending on the severity of the inherited UROS mutations and levels of porphyrins in plasma and erythrocytes. Severe disease can present in utero with hydrops fetalis, or shortly after birth with red urine, severe blistering photosensitivity, hemolysis, splenomegaly, and transfusion dependence. Repeated light exposure can lead to scarring, infection, and loss of facial features and digits. Skeletal changes may result from bone marrow expansion and vitamin D deficiency (Fritsch et al., 1997). Milder cases and later-onset forms, sometimes associated with a myeloproliferative disorder, can resemble PCT clinically (Deybach et al., 1981; Verstraeten et al., 1993; Murphy et al., 1995). These usually presents with red urine, severe blistering, and hemolytic anemia in infancy. Patients may develop photomutilation and become transfusion dependent.

In a study involving 130 cases of CEP, dermal deposits of uroporphyrin frequently induced dramatic phototoxic oxygen-dependent skin damage with extensive ulcerations and

mutilations. Splenomegaly and hemolytic anemia were typical internal symptoms. Skeletal changes such as osteolysis and calcifications were frequent (Fritsch et al., 1997).

Disease severity in unrelated patients is markedly heterogeneous, ranging from fetal demise or severe transfusion dependency throughout life to milder adult cases with only cutaneous photosensitivity. CEP should be suspected when severe photosensitivity begins in infancy or childhood, and porphyrins are markedly increased in both erythrocytes and urine. Pink to dark reddish urine or staining of the diaper noted shortly after birth may be the first clue to the diagnosis. Clinical severity of CEP is highly variable, ranging from non-immune hydrops fetalis due to severe hemolytic anemia in utero to milder, later-onset forms, which may have only cutaneous lesions in adult life. Mild to severe hemolysis is a feature of CEP and is accompanied by anisocytosis, poikilocytosis, polychromasia, basophilic stippling, reticulocytosis, increased circulating nucleated red cells, and absence of haptoglobin. Severe cutaneous photosensitivity usually begins in early infancy and is manifested by increased friability and blistering of the epidermis on the hands and face and other sun-exposed areas. Porphyrins deposited in the teeth produce a reddish-brown color in natural light, termed erythrodontia. The teeth may fluoresce on exposure to long-wavelength ultraviolet light (Deybach et al., 1980; Anderson, 2003; also see <http://www.porphyrifoundation.com/testing-for-porphyrin>).

Etiology and pathogenesis of CEP

CEP is an autosomal recessive genetic disorder characterized by markedly reduced enzyme activity of uroporphyrinogen III synthase (UROIII-S), the fourth enzyme in the heme biosynthetic pathway. A mutation of the UROIII-S gene was isolated as a full-length cDNA sequence (Desnick et al., 1998; Desnick and Astrin, 2002). CEP is characterized by severe overproduction of uroporphyrin I, which manifests at birth and in the neonatal period. UROS catalyzes the conversion of HMB, a linear tetrapyrrole, to the cyclic tetrapyrrole uroporphyrinogen III. In the absence of UROS, HMB undergoes spontaneous ring closure to uroporphyrinogen I, which can be further metabolized only to coproporphyrinogen I. Therefore, the isomer-I porphyrinogens are not heme precursors. They are spontaneously oxidized to uroporphyrin I and coproporphyrin I, which are photosensitizing porphyrins and

cause the cutaneous manifestations of CEP (Romeo and Levin, 1969; Romeo et al., 1970; Deybach et al., 1981; Tanigawa et al., 1995; Fritsch et al., 1997).

Multiple UROS mutations have been described in different families with CEP, including single base substitutions, insertions, deletions, and splicing defects (Warner et al., 1992; Xu et al., 1995; Ged et al., 1996; Desnick et al., 1998; Shady et al., 2002; Ged et al., 2004, 2009; Berry et al., 2005). Most mutations were identified in one or a few unrelated families, the exceptions being C73R, L4F, and T228M, which occurred in about 33%, 8%, and 7% of the mutant alleles studied, respectively. C73R is often associated with early onset of severe disease and transfusion-dependent hemolytic anemia, especially in homozygotes (Desnick and Astrin, 2002). Prokaryotic expression of mutant UROS alleles identified significant variation in residual activity, and elucidated genotype-phenotype correlation. In the largest series of biochemically proven CEP patients, UROS mutations were identified on 25 of 34 alleles (74%); no mutation was identified on either allele in three patients. The low sensitivity of mutation detection in this and other CEP case series is unexplained (Whatley and Badminton, 2013). Gain-of-function mutations of ALAS2 (the first enzyme of erythroid heme synthesis) can also influence the severity of CEP (Bunn, 2011; To-Figueras et al., 2011).

Erythropoietic Protoporphyrin (EPP) and X-Linked Protoporphyrin (XLP)

EPP is the third most common porphyria (10 to 20 per 100,000 individuals) and the most common in children, and was first clearly described by Magnus et al. (1961). The disease results from a deficiency of ferrochelatase (FECH) enzyme, leading to accumulation of protoporphyrin in erythrocytes, skin, liver, and other tissues. EPP causes a painful, non-blistering, life-long form of photosensitivity and, in about 2% of patients, severe liver disease. XLP is less common but has the same phenotype as EPP. XLP is the most recently described porphyria, and results from gain-of-function mutations of the erythroid-specific form of ALAS2, which catalyzes the first step in heme biosynthesis in marrow erythroid cells. A loss-of-function ALAS2 mutation causes X-linked sideroblastic anemia (Ducamp et al., 2011). EPP affects all ethnic groups without any sex predominance, but is more common in Asians than in Caucasians and much less common in Africans. The ethnic and geographic distribution of XLP has

been little studied, but XLP may be more common in the US than in Europe (Whatley and Badminton, 2013). Many individuals with EPP have a mild degree of anemia suggesting iron deficiency (Goerz et al., 1996).

Clinical features of EPP and XLP

Photosensitivity is the major clinical manifestation of EPP and XLP. Skin manifestations generally begin in early childhood and persist throughout life, are more severe in the summer (Anderson, 2003; Chemmanur and Bonkovsky, 2004; also see <http://www.porphyrifoundation.com/testing-for-porphyrin>). Sunlight (and to some extent other sources of visible light) cause very painful skin photosensitivity; however, the clinical expression is highly variable, and symptoms can vary even among patients within the same family. Swelling, burning, itching, and redness of the skin may appear during or after exposure to sunlight. Burning pain on sun-exposed areas of the skin ranges from mild to severe. Usually, these symptoms subside in 12 to 24 hr and heal without significant scarring. Blistering and scarring are characteristic of other types of cutaneous porphyria, but are unusual in EPP. Chronic skin lesions are minor and skin fragility is absent (Todd, 1994; Cox, 2003).

The need for affected individuals to avoid sunlight greatly impairs their quality of life. The first symptom following sun exposure is often pain, burning, or itching. Continued light exposure can cause swelling, redness, and systemic symptoms that can last for several days. Patients are sensitive to sunlight that passes through window glass. There are usually no lasting skin manifestations, such as blistering or scarring, although the skin may become thickened with repeated sun exposure, especially on the backs of the hands and the face (Anderson, 2003; Chemmanur and Bonkovsky, 2004; also see <http://www.porphyrifoundation.com/testing-for-porphyrin>). Mild iron deficiency anemia is a common feature of protoporphyria, and is poorly explained (Goerz et al., 1996). In the UK, delay in diagnosis of EPP and XLP is greater than with any other types of porphyria (Whatley and Badminton, 2013). EPP rarely develops in adults in the presence of a myeloproliferative disorder, due to expansion of a clone of red blood cell precursors in the marrow that is FECH deficient.

The accumulation of protoporphyrin can cause liver damage when the hepatic load exceeds the canalicular excretion capacity. Ap-

proximately 2% of patients with protoporphyria develop protoporphyric hepatopathy, a severe liver disease that can progress rapidly and require liver transplantation (Sarkany and Cox, 1995; Bloomer et al., 2005; McGuire et al., 2005; Elder et al., 2009; Dowman et al., 2011).

The most effective treatment is prevention of the photosensitive reaction by avoiding sunlight and protecting the skin with clothing and occlusive sunscreen preparations. Increasing skin pigmentation with afamelanotide, an α -melanocyte-stimulating hormone analog, can significantly increase sunlight tolerance (Holme et al., 2006; Minder, 2010; Langendonk et al., 2015).

Etiology and pathogenesis of EPP and XLP

EPP is caused by mutations in the gene encoding FECH, a mitochondrial enzyme that catalyzes the insertion of ferrous iron (Fe^{2+}) into protoporphyrin to form heme (Todd, 1994; Poh-Fitzpatrick, 1995; Cox, 1997; Elder, 1999). FECH also catalyzes the insertion of zinc, to form zinc protoporphyrin from any protoporphyrin that remains after completion of heme synthesis. In EPP, metal-free protoporphyrin accumulates in bone marrow reticulocytes, since formation of both heme and zinc protoporphyrin is impaired. Metal-free protoporphyrin enters the plasma from the bone marrow and circulating erythrocytes and is then transported to the skin, causing photosensitivity, and to the liver for excretion into bile (Bloomer et al., 1991, 2005) and hepatocytes (Bonkovsky et al., 1975; Samuel et al., 1988; Bloomer et al., 1991, 2005). Some protoporphyrin may subsequently be reabsorbed and undergo enterohepatic circulation (Ibrahim and Watson, 1968). Because impaired FECH activity reduces formation of zinc protoporphyrin, more than ~85% of protoporphyrin measured in erythrocytes is metal-free.

More than 130 FECH mutations have been identified in EPP (HGMD, <http://www.biobase-international.com/product/hgmd>).

Less than half are missense, and the rest are nonsense, frameshifts, large deletions, or RNA splicing. In the UK, one particular mutation was identified in 24% of EPP families (Whatley et al., 2010). Most FECH mutations are disabling mutations that reduce FECH activity by ~50%, which is not a sufficient reduction to cause EPP. Most individuals with EPP have a disabling FECH mutation from one parent and a low-expression (hypomorphic)

FECH allele from the other (Gouya et al., 1996). The low-expression intronic variant (IVS3-48 C/T) produces a truncated unstable mRNA, reducing enzyme activity by 20-30% (Gouya et al., 2002). It is common in the population, but does not by itself cause disease. The combination of two allelic variants reduces overall FECH activity to 35% of normal or less, causing accumulation of protoporphyrin during hemoglobin synthesis (Gouya et al., 2006). The low-expression FECH allele is found in ~10% of Caucasians, is more common in Asian populations and very rare in Africa, thus accounting for the rarity of EPP among those of African descent. Rarely, two disabling mutations are present, with at least one expressing enough FECH protein to complete heme synthesis, since complete absence of heme synthesis would be lethal. In families with two disabling FECH mutations, EPP is associated with palmar keratoderma. The reason for this is unknown.

EPP rarely develops in adults in the presence of a bone marrow disorder such as polycythemia vera, and is due to expansion of a clone of red blood cell precursors in the marrow that is deficient in FECH enzyme. In PCT, liver disease may develop through different mechanisms (i.e., type 1 and type 2 PCT), whereas, in EPP, it is the porphyria itself that leads to liver disease, due to progressive deposition and accumulation of insoluble protoporphyrin IX in hepatocytes and bile canaliculi. Excess accumulation of free protoporphyrin IX results from partial deficiency of FECH enzyme activity. EPP is an inherited disorder with both recessive and dominant patterns of inheritance (Went and Klasen, 1984; Lamoril et al., 1991; Norris et al., 1991; Sarkany et al., 1994).

XLP results from gain-of-function mutations of ALAS2, the only enzyme in the heme biosynthetic pathway encoded by a gene on the X chromosome. These small, C-terminal deletion mutations lead to synthesis of ALA and protoporphyrin in amounts that exceed what is needed for heme synthesis in the bone marrow. Because FECH is not deficient in XLP, some of the excess protoporphyrin measured in erythrocytes is zinc-chelated, and only ~50% to 85% is metal-free. On average, patients with XLP have more severe disease, with higher protoporphyrin levels and perhaps a greater risk of liver disease, than patients with EPP. Heterozygous females may have normal or elevated levels of protoporphyrin depending on the degree of inactivation of the X chromo-

some that carries the ALAS2 mutation (Whatley et al., 2008).

ACKNOWLEDGEMENTS

Support from NIH/FDA (5 R01 FD003720-02) and NIH (2 U54 DK083909-06) grants (to K.E.A., principal investigator) are gratefully acknowledged.

LITERATURE CITED

- Aarsand, A.K., Boman, H., and Sandberg, S. 2009. Familial and sporadic porphyria cutanea tarda: Characterization and diagnostic strategies. *Clin. Chem.* 55:795-803.
- Akagi, R., Kato, N., Inoue, R., Anderson, K.E., Jaffe, E.K., and Sassa, S. 2006. δ -Aminolevulinic acid dehydratase (ALAD) porphyria: The first case in North America with two novel ALAD mutations. *Mol. Genet. Metab.* 87:329-336.
- Albers, J.W., Robertson, W.C. Jr., and Daube, J.R. 1978. Electrodiagnostic findings in acute porphyric neuropathy. *Muscle Nerve* 1:292-296.
- Anderson, K.E. 2003. Approaches to treatment and prevention of human porphyrias. In *The Porphyrin Handbook*, Vol. 14: Medical Aspects of Porphyrins (K.K. Kadish, K.M. Smith, and R. Guillard, eds.) pp. 247-283. Academic Press, San Diego, Calif.
- Anderson, K.E. 2014. Chapter 152. Clinical and laboratory diagnosis of the porphyrias. In *Handbook of Porphyrin Science with Applications in Chemistry, Physics, Materials Science, Engineering, Biology, and Medicine*, Vol. 29: Porphyrins and Sideroblastic Anemias (G.C. Ferreira, K.M. Kadish, K.M. Smith, and R. Guillard, eds.) pp. 370-406. World Scientific Publishing, Hackensack, N.J.
- Anderson, K.E., Drummond, G.S., Freddara, U., Sardana, M.K., and Sassa, S. 1981. Porphyrigenic effects and induction of heme oxygenase in vivo by δ -aminolevulinic acid. *Biochim. Biophys. Acta* 676:289-299.
- Anderson, K.E., Sassa, S., Bishop, D.F., and Desnick, R.J. 2001. Disorders of heme biosynthesis: X-linked sideroblastic anemias and the porphyrias. In *The Metabolic and Molecular Basis of Inherited Disease*, 8th ed., Vol. II (C.R. Scriver, A.L. Beaudet, W.S. Sly, et al., eds.) pp. 2991-3062. McGraw-Hill, New York.
- Anderson, K.E., Bloomer, J.R., Bonkovsky, H.L., Kushner, J.P., Pierach, C.A., Pimstone, N.R., and Desnick, R.J. 2005. Recommendations for the diagnosis and treatment of the acute porphyrias. *Ann. Intern. Med.* 142:439-450.
- Anderson, K.E., Sassa, S., Bishop, D.F., and Desnick, R.J. 2011. *The Online Metabolic & Molecular Basis of Inherited Disease* (D.F. Bishop, ed.) pp. 1-153. McGraw-Hill, New York.
- Armstrong, D.K., Sharpe, P.C., Chambers, C.R., Whatley, S.D., Roberts, A.G., and Elder, G.H.

2004. Hepatoerythropoietic porphyria: A missense mutation in the UROD gene is associated with mild disease and an unusual porphyrin excretion pattern. *Br. J. Dermatol.* 151:920-923.
- Badenas, C., To-Figueras, J., Phillips, J.D., Warby, C.A., Munoz, C., and Herrero, C. 2009. Identification and characterization of novel uroporphyrinogen decarboxylase gene mutations in a large series of porphyria cutanea tarda patients and relatives. *Clin. Genet.* 75:346-353.
- Badminton, M.N. and Elder, G.H. 2002. Management of acute and cutaneous porphyrias. *Int. J. Clin. Pract.* 56:272-278.
- Badminton, M.N. and Elder, G.H. 2005. Molecular mechanisms of dominant expression in porphyria. *J. Inherit. Metab. Dis.* 28:277-286.
- Badminton, M.N., Wheatley, S.D., Deacon, A.C., and Elder, G.H. 2012. The porphyrias and other disorders of porphyrin metabolism. In *Tietz Textbook of Clinical Chemistry and Molecular Diagnostics*, 5th ed. (C.A. Burtis, E.R. Ashwood, and D.E. Bruns, eds.) pp. 1031-1055. Elsevier Saunders, St. Louis, Missouri.
- Badminton, M.N., Elder, G.H., and Whatley, S.D. 2014. Clinical and molecular epidemiology of the porphyrias. In *Handbook of Porphyrin Science with Applications in Chemistry, Physics, Materials Science, Engineering, Biology, and Medicine*, Vol. 29: Porphyrias and Sideroblastic Anemias (G.C. Ferreira, K.M. Kadish, K.M. Smith, and R. Guillard, eds.) pp. 119-150. World Scientific Publishing, Hackensack, N.J.
- Balwani, M. and Desnick, R.J. 2012. The porphyrias: Advances in diagnosis and treatment. *Blood* 120:4496-4504.
- Barbaro, M., Kotajärvi, M., Harper, P., and Floderus, Y. 2012. Identification of an AluY-mediated deletion of exon 5 in the CPOX gene by MLPA analysis in patients with hereditary coproporphyrin. *Clin. Genet.* 81:249-256.
- Berenguer, J., Blasco, J., Cardenal, C., Pujol, T., Cruces Prado, M.J., Herrero, C., Mascaró, J.M., de la Torre, C., and Mercader, J.M. 1997. Hepatoerythropoietic porphyria: Neuroimaging findings. *Am. J. Neuroradiol.* 18:1557-1560.
- Bergdahl, I.A., Grubb, A., Schütz, A., Schutz, A., Desnick, R.J., Wetmur, J.G., Sassa, S., and Skerfving, S. 1997. Lead binding to δ -aminolevulinic acid dehydratase (ALAD) in human erythrocytes. *Pharmacol. Toxicol.* 81:153-158.
- Berry, A.A., Desnick, R.J., Astrin, K.H., Shabeer, J., Lucky, A.W., and Lim, H.W. 2005. Two brothers with mild congenital erythropoietic porphyria due to a novel genotype. *Arch. Dermatol.* 141:1575-1579.
- Bird, T.D., Hamernyik, P., Nutter, J.Y., and Labbe, R.F. 1979. Inherited deficiency of δ -aminolevulinic acid dehydratase. *Am. J. Hum. Genet.* 31:662-668.
- Bissell, D.M., Wang, B., Cimino, T., and Lai, J. 2012. Hereditary coproporphyrin. In *GeneReviews* (Internet) (R.A. Pagon, M.P. Adam, and H.H. Ardinger, et al., eds.). University of Washington, Seattle, Washington. <http://www.ncbi.nlm.nih.gov/books/NBK114807/>.
- Blake, D., McManus, J., Cronin, V., and Ratnaik, S. 1992. Fecal coproporphyrin isomers in hereditary coproporphyrin. *Clin. Chem.* 38:96-100.
- Blauvelt, A. 1996. Hepatitis C virus and human immunodeficiency virus infection can alter porphyrin metabolism and lead to porphyria cutanea tarda. *Arch. Dermatol.* 132:1503-1504.
- Bleasel, N.R. and Varigos, G.A. 2000. Porphyria cutanea tarda. *Aust. J. Dermatol.* 41:197-208.
- Bleiberg, J., Wallen, M., Brodtkin, R., and Applebaum, I.L. 1964. Industrially acquired porphyria. *Arch. Dermatol.* 80:793-797.
- Bloomer, J.R. and Bonkovsky, H.L. 1989. The porphyrias. *Dis. Mon.* 35:5-54.
- Bloomer, J.R., Hill, H.D., Kools, A.M., and Straka, J.G. 1991. Heme synthesis in protoporphyria. *Curr. Probl. Dermatol.* 20:135-147.
- Bloomer, J., Wang, Y., Singhal, A., and Risheg, H. 2005. Molecular studies of liver disease in erythropoietic protoporphyria. *J. Clin. Gastroenterol.* 39:S167-S175.
- Boisseau, A.M., Couzigou, P., Forestier, J.F., Legrain, V., Aubertin, J., Doutre, M.S., Maleville, J., Geniaux, M., and Beylot, C. 1991. Porphyria cutanea tarda associated with human immunodeficiency virus infection. A study of four cases and review of the literature. *Dermatologica* 182:155-159.
- Bonkovsky, H.L. 1982. Porphyrin and heme metabolism and the porphyrias. In *Hepatology: A Textbook of Liver Disease* (D. Zakim and T. Boyer, eds.) pp. 351-393. Saunders, Philadelphia, Penn.
- Bonkovsky, H.L. 1989. Mechanism of iron potentiation of hepatic uroporphyrin: Studies in cultured chick embryo liver cells. *Hepatology* 10:354-364.
- Bonkovsky, H.L., Bloomer, J.R., Ebert, P.S., and Mahoney, M.J. 1975. Heme synthetase deficiency in human protoporphyria. Demonstration of the defect in liver and cultured skin fibroblasts. *J. Clin. Invest.* 56:1139-1148.
- Bonkovsky, H.L., Healey, J.F., Lincoln, B., Bacon, B.R., Bishop, D.F., and Elder, G.H. 1987. Hepatic heme synthesis in a new model of experimental hemochromatosis: Studies in rats fed finely divided elemental iron. *Hepatology* 7:1195-1203.
- Bonkovsky, H.L., Healey, J.F., and Pohl, J. 1990. Purification and characterization of heme oxygenase from chick liver: Comparison of the avian and mammalian enzymes. *Eur. J. Biochem.* 189:155-166.
- Bonkovsky, H.L., Poh-Fitzpatrick, M., Pimstone, N., Obando, J., Di Bisceglie, A., Tattre, C., Tortorelli, K., LeClair, P., Mercurio, M.G., and Lambrecht, R.W. 1998. Porphyria cutanea tarda, hepatitis C, and HFE gene mutations in North America. *Hepatology* 27:1661-1669.

- Bovenschen, H.J. and Vissers, W.H.P.M. 2009. Primary hemochromatosis presented by porphyria cutanea tarda: A case report. *Cases J.* 2:7246.
- Brenner, D.A. and Bloomer, J.R. 1980. The enzymatic defect in variegate porphyria. Studies with human cultured skin fibroblasts. *N. Engl. J. Med.* 302:765-769.
- Brodie, M.J., Thompson, G.G., Moore, M.R., Beatie, A.D., and Goldberg, A. 1977. Hereditary coproporphyrin. Demonstration of the abnormalities in haem biosynthesis in peripheral blood. *Q. J. Med.* 46:229-241.
- Bunn, H.F. 2011. UROS and ALAS-2: Erstwhile partners in crime. *Blood* 118:1435-1437.
- Bygum, A., Christiansen, L., Peterson, N.E., Horder, M., Thomsen, K., and Brandrup, F. 2003. Familial and sporadic porphyria cutanea tarda: Clinical, biochemical and genetic features with emphasis on iron status. *Acta Derm. Venereol.* 83:115-120.
- Bylesjo, I., Wikberg, A., and Andersson, C. 2009. Clinical aspects of acute intermittent porphyria in northern Sweden: A population-based study. *Scand. J. Clin. Lab. Invest.* 69:612-618.
- Cam, C. and Nigogosyan, G. 1963. Acquired toxic porphyria cutanea tarda due to hexachlorobenzene. *J. Am. Med. Assoc.* 183:88-91.
- Campbell, A.E., Wilkinson-White, L., Mackay, J.P., Mathews, J.M., and Blobel, G.A. 2013. Analysis of disease-causing GATA1 mutations in murine gene complementation systems. *Blood* 121:5218-5227.
- Cantatore-Francis, J.L., Cohel, J., Balwani, M., Khan, P., Lazarus, H.M., Desnick, R.J., and Schaffer, J.V. 2010. Hepatoerythropoietic porphyria misdiagnosed as child abuse: Cutaneous, arthritic and hematologic manifestations in siblings with a novel UROD mutation. *Arch. Dermatol.* 146:529-533.
- Chemmanur, A.T. and Bonkovsky, H.L. 2004. Hepatic porphyrias: Diagnosis and management. *Clin. Liver Dis.* 8:807-838.
- Chiaverini, C., Halimi, G., Ouzan, D., Halfon, P., Ortonne, J.P., and Lacour, J.P. 2003. Porphyria cutanea tarda, C282Y, H63D and S65C HFE gene mutations and hepatitis C infection: A study from southern France. *Dermatology* 206:212-216.
- Chuang, T.Y., Brashear, R., and Lewis, C. 1999. Porphyria cutanea tarda and hepatitis C virus: A case-control study and meta-analysis of the literature. *J. Am. Acad. Dermatol.* 41:31-36.
- Cox, T.M. 1997. Erythropoietic protoporphyria. *J. Inherit. Metab. Dis.* 20:258-269.
- Cox, T. 2003. Protoporphyrin. In *The Porphyrin Handbook* (K.M. Kadish, K.M. Smith, and R. Guillard, eds.) pp. 121-150. Academic Press, Amsterdam.
- Cribier, B., Rey, D., Uhl, G., Le Coz, C., Hirth, C., Libbrecht, E., Vetter, D., Lang, J.M., Stoll-Keller, F., and Grosshans, E. 1996. Abnormal urinary coproporphyrin levels in patients infected by hepatitis C virus with or without human immunodeficiency virus. A study of 177 patients. *Arch. Dermatol.* 132:1448-1452.
- Cribier, B., Chiaverini, C., Dali-Youcef, N., Schmitt, M., Grima, M., Hirth, C., Lacour, J.P., and Chosidow, O. 2009. Porphyria cutanea tarda, hepatitis C, uroporphyrinogen decarboxylase and mutations of HFE gene. A case-control study. *Dermatology* 218:15-21.
- Cripps, D.J., Peters, H.A., Gocmen, A., and Dogramici, I. 1984. Porphyria turcica due to hexachlorobenzene: A 20-30 year follow-up study on 204 patients. *Br. J. Dermatol.* 111:413-422.
- Dabrowska, E., Jablonska-Kaszewska, I., and Falkiewicz, B. 1998. High prevalence of hepatitis C virus infection in patients with porphyria cutanea tarda in Poland. *Clin. Exp. Dermatol.* 23:95-96.
- D'Alessandro Gandolfo, L., Griso, D., Macri, A., Biolcati, G., and Topi, G.C. 1989. Familial porphyria cutanea tarda with normal erythrocytic urodecarboxylase: An exception to the rule? *Dermatologica* 178:206-208.
- Day, R.S. and Strauss, P.C. 1982. Severe cutaneous porphyria in a 12-year-old boy: Hepatoerythropoietic or symptomatic porphyria? *Arch. Dermatol.* 118:663-667.
- De Matteis, F. 1998. Porphyria cutanea tarda of the toxic and sporadic varieties. *Clin. Dermatol.* 16:265-275.
- Desnick, R.J. and Astrin, K.H. 2002. Congenital erythropoietic porphyria: Advances in pathogenesis and treatment. *Br. J. Haematol.* 117:779-795.
- Desnick, R.J., Glass, I.A., Xu, W., Solis, C., and Astrin, K.H. 1998. Molecular genetics of congenital erythropoietic porphyria. *Semin. Liver Dis.* 18:77-84.
- Desnick, R.J., Balwani, M., and Anderson, K.E. 2013. Inherited porphyrias. In *Emory and Rimoins's Essential Medical Genetics* (D.L. Rimoins, R.E. Pyeritz, and B. Korf, eds.). Academic Press, Kidlington, Oxford.
- Deybach, J.C., Grandchamp, B., Grelier, M., Nordmann, Y., Boué, J., Boué, A., and de Berrianger, P. 1980. Prenatal exclusion of congenital erythropoietic porphyria (Gunther's disease) in a fetus at risk. *Hum. Genet.* 53:217-221.
- Deybach, J.C., de Verneuil, H., Phung, N., Nordmann, Y., Puissant, A., and Boffety, B. 1981. Congenital erythropoietic porphyria (Gunther's disease): Enzymatic studies on two cases of late onset. *J. Lab. Clin. Med.* 97:551-558.
- Deybach, J.C., Badminton, M., Puy, H., Sandberg, S., Frank, J., Harper, P., Martasek, P., Minder, E., Parker, S., Thunell, S., and Elder, G. 2006. European porphyria initiative (EPI): A platform to develop a common approach to the management of porphyrias and to promote research in the field. *Physiol. Res.* 55:S67-S73.
- Di Pierro, E., Besana, V., Moriondo, V., Brancaleoni, V., Tavazzi, D., Casalgrandi, G., Ventura, P., Rocchi, E., and Cappellini, M.D. 2006. A large

- deletion on chromosome 11 in acute intermittent porphyria. *Blood Cells Mol. Dis.* 37:50-54.
- Doss, M. and Schmidt, A. 1972. Zwei suchteste für porphyrien. *Z. Klin. Chem. Klin. Biochem.* 10:230-231.
- Doss, M., Laubenthal, F., and Stoeppler, M. 1984. Lead poisoning in inherited δ -aminolevulinic acid dehydratase deficiency. *Int. Arch. Occup. Environ. Health* 54:55-63.
- Doss, M.O., Frank, M., and Braun-Falco, O. 1991. Porphyria cutanea tarda: Erythrocyte uroporphyrinogen decarboxylase activity in 471 consecutive patients. *Curr. Probl. Dermatol.* 20:97-105.
- Doss, M.O., Stauch, T., Gross, U., Renz, M., Akagi, R., Doss-Frank, M., Seelig, H.P., and Sassa S. 2004. The third case of Doss porphyria (δ -amino-levulinic acid dehydratase deficiency) in Germany. *J. Inherit. Metab. Dis.* 27:529-536.
- Dowman, J.K., Gunson, B.K., Bramhall, S., Badminton, M.N., and Newsome, P.N. 2011. Liver transplantation from donors with acute intermittent porphyria. *Ann. Intern. Med.* 154:571-572.
- Ducamp, S., Kannengiesser, C., Touati, M., Garçon, L., Guerci-Bresler, A., Guichard, J.F., Vermeylen, C., Dochir, J., Poirel, H.A., Fouyssac, F., Mansuy, L., Leroux, G., Tertian, G., Girot, R., Heimpele, H., Matthes, T., Talbi, N., Deybach, J.C., Beaumont, C., Puy, H., and Grandchamp, B. 2011. Sideroblastic anemia: Molecular analysis of the ALAS2 gene in a series of 29 probands and functional studies of 10 missense mutations. *Hum. Mutat.* 32:590-597.
- Ducamp, S., Schneider-Yin, X., de Rooij, F., Clayton, J., Fratz, E.J., Rudd, A., Ostapowicz, G., Varigos, G., Lefebvre, T., Deybach, J.C., Gouya, L., Wilson, P., Ferreira, G.C., Minder, E.I., and Puy, H. 2013. Molecular and functional analysis of the C-terminal region of human erythroid-specific 5-aminolevulinic synthase associated with X-linked dominant protoporphyria (XLDPP). *Hum. Mol. Genet.* 22:1280-1288.
- Eales, L., Day, R.S., and Blekkenhorst, G.H. 1980. The clinical and biochemical features of variegate porphyria: An analysis of 300 cases studied at Groote Schuur Hospital, Cape Town. *Int. J. Biochem.* 12:837-853.
- Egger, N.G., Goeger, D.E., Payne, D.A., Miskovsky, E.P., Weinman, S.A., and Anderson, K.E. 2002. Porphyria cutanea tarda: Multiplicity of risk factors including HFE mutations, hepatitis C, and inherited uroporphyrinogen decarboxylase deficiency. *Digest. Dis. Sci.* 47:419-426.
- Elder, G.H. 1990. Porphyria cutanea tarda: A multifactorial disease. *Recent Adv. Dermatol.* 8:55-69.
- Elder, G.H. 1997. Hepatic porphyrias in children. *J. Inherit. Metab. Dis.* 20:237-246.
- Elder, G.H. 1998. Porphyria cutanea tarda. *Semin. Liver Dis.* 18:67-75.
- Elder, G.H. 1999. The cutaneous porphyrias. In *Photodermatology* (J.L.M. Hawk, ed.) pp. 171-197. Chapman & Hall, London.
- Elder, G.H. 2003. Porphyria cutanea tarda and related disorders. In *The Porphyrin Handbook*, Vol. 14 (K. Kadish, K. Smith, and R. Guillard, eds.) p. 67. Elsevier Science, San Diego.
- Elder, G.H. and Roberts, A.G. 1995. Uroporphyrinogen decarboxylase. *J. Bioenerg. Biomembr.* 27:207-214.
- Elder, G.H. and Worwood, M. 1998. Mutations in the hemochromatosis gene, porphyria cutanea tarda, and iron overload. *Hepatology* 27:289-291.
- Elder, G.H., Smith, S.G., Herrero, C., Lecha, M., Mascaro, J.M., Muniesa, A.M., Czarniecki, D.B., Brenan, J., Poulos, V., and de Salamanca, R.E. 1981. Hepatoerythropoietic porphyria: A new uroporphyrinogen decarboxylase defect or homozygous porphyria cutanea tarda? *Lancet* 1:916-919.
- Elder, G.H., Urquhart, A.J., de Salamanca, R.E., Munoz, J.J., and Bonkovsky, H. 1985. Immunoreactive uroporphyrinogen decarboxylase in the liver in porphyria cutanea tarda. *Lancet* 2:229-232.
- Elder, G.H., Roberts, A.G., and de Salamanca, R.E. 1989. Genetics and pathogenesis of human uroporphyrinogen decarboxylase defects. *Clin. Biochem.* 22:163-168.
- Elder, G.H., Gouya, L., Whatley, S.D., Puy, H., Badminton, M.N., and Deybach, J.C. 2009. The molecular genetics of erythropoietic protoporphyria. *Cell. Mol. Biol.* 55:118-126.
- Elder, G.H., Harper, P., Badminton, M., Sandberg, S., and Deybach, J.C. 2013. The incidence of inherited porphyrias in Europe. *J. Inherit. Metab. Dis.* 36:849-857.
- Felsher, B.F., Jones, M.L., and Redeker, A.G. 1973. Iron and hepatic uroporphyrin synthesis. Relation in porphyria cutanea tarda. *J. Am. Med. Assoc.* 226:663-665.
- Fernández-Cuartero, B., Rebollar, J.L., Batlle, A., and Enriquez de Salamanca, R. 1999. Delta-aminolevulinic acid dehydratase (ALA-D) activity in human and experimental diabetes mellitus. *Int. J. Biochem. Cell Biol.* 31:479-488.
- Floderus, Y., Shoolingin-Hordan, P.M., and Harper, P. 2002. Acute intermittent porphyria in Sweden. Molecular, functional and clinical consequences of some new mutations found in the porphobilinogen deaminase gene. *Clin. Genet.* 62:288-297.
- Fodinger, M. and Sunder-Plassmann, G. 1999. Inherited disorders of iron metabolism. *Kidney Int. Suppl.* 69:S22-S34.
- Francanzani, A.L., Taioli, E., Sampietro, M., Fatta, E., Bertelli, C., Fiorelli, G., and Fargion, S. 2001. Liver cancer risk is increased in patients with porphyria cutanea tarda in comparison to matched control patients with chronic liver disease. *J. Hepatol.* 35:498-503.
- Frank, J. and Poblete-Gutierrez, P. 2010. Porphyria cutanea tarda—when skin meets liver. *Best Pract. Res. Clin. Gastroenterol.* 24:735-745.

- Frank, J., McGrath, J., Lam, H., Graham, R.M., Hawk, J.L., and Christiano, A.M. 1998. Homozygous variegate porphyria: Identification of both alleles of the protoporphyrinogen oxidase gene in a severely affected proband. *J. Invest. Dermatol.* 110:452-455.
- Fritsch, C., Bolsen, K., Ruzicka, T., and Goerz, G. 1997. Congenital erythropoietic porphyria. *J. Am. Acad. Dermatol.* 36:594-610.
- Fujita, H., Koizumi, A., Yamamoto, M., Kumai, M., Sadamoto, T., and Ikeda, M. 1984. Inhibition of δ -aminolevulinic acid dehydratase in trichloroethylene-exposed rats, and the effects on heme regulation. *Biochim. Biophys. Acta* 800:1-10.
- Fujita, H., Koizumi, A., Hayashi, N., and Ikeda, M. 1986. Reduced synthesis of 5-aminolevulinic acid dehydratase in styrene-treated rats. *Biochim. Biophys. Acta* 867:89-96.
- Fujita, H., Sassa, S., Toback, A.C., and Kappas, A. 1987. Immunohistochemical study of uroporphyrinogen decarboxylase in a patient with mild hepatoerythropoietic porphyria. *J. Clin. Invest.* 79:1533-1537.
- Garey, J.R., Harrison, L.M., Franklin, K.F., Metcalf, K.M., Radisky, E.S., and Kushner, J.P. 1990. Uroporphyrinogen decarboxylase: A splice site mutation causes the deletion of exon 6 in multiple families with porphyria cutanea tarda. *J. Clin. Invest.* 86:1416-1422.
- Garey, J.R., Franklin, K.F., Brown, D.A., Harrison, L.M., Metcalf, K.M., and Kushner, J.P. 1993. Analysis of uroporphyrinogen decarboxylase complementary DNAs in sporadic porphyria cutanea tarda. *Gastroenterology* 105:165-169.
- Ged, C., Moreau-Gaudry, F., Taine, L., Hombrados, I., Calvas, P., Colombies, P., and De Verneuil, H. 1996. Prenatal diagnosis in congenital erythropoietic porphyria by metabolic measurement and DNA mutation analysis. *Prenatal Diagn.* 16:83-86.
- Ged, C., Megarbane, H., Chouery, E., Lalanne, M., Megarbane, A., and de Verneuil, H. 2004. Congenital erythropoietic porphyria: Report of a novel mutation with absence of clinical manifestations in a homozygous mutant sibling. *J. Invest. Dermatol.* 123:589-591.
- Ged, C., Moreau-Godry, F., Richard, E., Robert-Richard, E., and de Verneuil, H. 2009. Congenital erythropoietic porphyria: Mutation update and correlations between genotype and phenotype. *Cell. Mol. Biol.* 55:53-60.
- Gisbert, J.P., Garcia-Buey, L., Pajares, J.M., and Moreno-Otero, R. 2003. Prevalence of hepatitis C virus infection in porphyria cutanea tarda: Systematic review and meta-analysis. *J. Hepatol.* 39:620-627.
- Goerz, G., Bunselmeyer, S., Bolsen, K., and Schürer, N.Y. 1996. Ferrochelatase activities in patients with erythropoietic protoporphyria and their families. *Br. J. Dermatol.* 134:880-885.
- Gomi, H., Hatanaka, K., Miura, T., and Matsuo, I. 1997. Type of impaired porphyrin metabolism caused by hepatitis C virus is not porphyria cutanea tarda but chronic hepatic porphyria. *Arch. Dermatol.* 133:1170-1171.
- Gouya, L., Deybach, J.C., Lamoril, J., Da Silva, V., Beaumont, C., Grandchamp, B., and Nordmann, Y. 1996. Modulation of the phenotype in dominant erythropoietic protoporphyria by a low expression of the normal ferrochelatase allele. *Am. J. Hum. Genet.* 58:292-299.
- Gouya, L., Puy, H., Robreau, A.M., Bourgeois, M., Lamoril, J., Da Silva, V., Grandchamp, B., and Deybach, J.C. 2002. The penetrance of dominant erythropoietic protoporphyria is modulated by expression of wildtype FECH. *Nat. Genet.* 30:27-28.
- Gouya, L., Martin-Schmitt, C., Robreau, A.M., Austerlitz, F., Da Silva, V., Brun, P., Simonin, S., Lyoumi, S., Grandchamp, B., Beaumont, C., Puy, H., and Deybach, J.C. 2006. Contribution of a common single-nucleotide polymorphism to the genetic predisposition for erythropoietic protoporphyria. *Am. J. Hum. Genet.* 78:2-14.
- Granata, B.X., Parera, V.E., Melito, V.A., Teijo, M.J., Batlle, A.M., and Rossetti, M.V. 2009. The very first description of a patient with hepatoerythropoietic porphyria in Argentina: Biochemical and molecular studies. *Cell. Mol. Biol.* 55:61-65.
- Grandchamp, B., Picat, C., Mignotte, V., Wilson, J.H., Te Velde, K., Sandkuyl, L., Roméo, P.H., Goossens, M., and Nordmann, Y. 1989. Tissue-specific splicing mutation in acute intermittent porphyria. *Proc. Natl. Acad. Sci. U.S.A.* 86:661-664.
- Granick, J.L., Sassa, S., and Kappas, A. 1978. Some biochemical and clinical aspects of lead intoxication. In *Advances in Clinical Chemistry* (O. Bodansky and A.L. Latner, eds.) pp. 287-339. Academic Press, New York.
- Grossman, M.E. and Poh-Fitzpatrick, M.B. 1980. Porphyria cutanea tarda. Diagnosis and management. *Med. Clin. North Am.* 64:807-827.
- Grossman, M.E., Bickers, D.R., Poh-Fitzpatrick, M.B., Deleo, V.A., and Harber, L.C. 1979. Porphyria cutanea tarda. Clinical features and laboratory findings in 40 patients. *Am. J. Med.* 67:277-286.
- Gunther, W.W. 1967. The porphyrias and erythropoietic porphyria: An unusual case. *Australas J. Dermatol.* 9:23-30.
- Guolo, M., Stella, A.M., Melito, V., Parera, V., and Del C. Batlle, A.M. 1996. Altered 5-aminolevulinic acid metabolism leading to pseudoporphyria in hemodialysed patients. *Int. J. Biochem. Cell Biol.* 28:311-317.
- Hahn, M. and Bonkovsky, H.L. 1998. Disorders of porphyrin metabolism. In *Diseases of the Liver and Bile Ducts: A Practical Guide to Diagnosis and Treatment* (G. Wu and J. Israel, eds.) pp. 249-272. Humana Press, Totowa, N.J.
- Held, J.L., Sassa, S., Attalah, K., and Harber, L.C. 1989. Erythrocyte uroporphyrinogen decarboxylase activity in porphyria cutanea tarda: A study of 40 consecutive patients. *J. Invest. Dermatol.* 93:332-334.

- Herrick, A.L. and McColl, K.E.L. 2005. Acute intermittent porphyria. *Best Pract. Res. Clin. Gastroenterol.* 19:235-249.
- Hift, R.J., Meissner, P.N., Corrigan, A.V., Ziman, M.R., Petersen, L.A., Meissner, D.M., Davidson, B.P., Sutherland, J., Dalley, H.A., and Kirsch, R.E. 1997. Variegated porphyria in South Africa, 1688-1996—New developments in an old disease. *S. Afr. Med. J.* 87:722-731.
- Hift, R.J., Meissner, D., and Meissner, P.N. 2004. A systematic study of the clinical and biochemical expression of variegated porphyria in a large South African family. *Brit. J. Dermatol.* 151:465-471.
- Holme, S.A., Anstey, A.V., Finlay, A.Y., Elder, G.H., and Badminton, M.N. 2006. Erythropoietic protoporphyria in the U.K.: Clinical features and effect on quality of life. *Br. J. Dermatol.* 155:574-581.
- Horina, J.H. and Wolf, P. 2000. Epoetin for severe anemia in hepatoerythropoietic porphyria. *N. Engl. J. Med.* 342:1294-1295.
- Ibrahim, G.W. and Watson, C.J. 1968. Enterohepatic circulation and conversion of protoporphyrin to bile pigment in man. *Proc. Soc. Exp. Biol. Med.* 127:890-895.
- Innala, E. and Andersson, C. 2011. Screening for hepatocellular carcinoma in acute intermittent porphyria: A 15-year follow-up in northern Sweden. *J. Intern. Med.* 269:538-545.
- Jaffe, E.K. and Stith, L. 2007. ALAD porphyria is a conformational disease. *Am. J. Hum. Genet.* 80:329-337.
- Jalil, S., Grady, J.J., Lee, C., and Anderson, K.E. 2010. Associations among behavior-related susceptibility factors in porphyria cutanea tarda. *Clin. Gastroenterol. Hepatol.* 8:297-302.
- Jordan, P.M. 1990. The biosynthesis of 5-aminolevulinic acid and its transformation into coproporphyrinogen in animals and bacteria. In *Biosynthesis of Heme and Chlorophylls* (H.A. Dailey, ed.) pp. 55-121. McGraw-Hill, New York.
- Kappas, A., Sassa, S., and Anderson, K.E. 1983. The porphyrias. In *The Metabolic Basis of Inherited Disease*, 5th ed. (J.B. Stanbury, J.B. Wyngaarden, D.S. Fredrickson, J.L. Goldstein, and M.S. Brown, eds.) pp. 1301-1384. McGraw-Hill, New York.
- Kappas, A., Sassa, S., Galbraith, R.A., and Nordmann, Y. 1995. The porphyrias. In *Metabolic and Molecular Bases of Inherited Disease*, Vol. 2, 7th ed. (C.R. Scriver, A.L. Beaudet, W.S. Sly, and D. Valle, eds.) pp. 2103-2159. McGraw-Hill, New York.
- Kauppinen, R., Timonen, K., von und zu Fraunberg, M., Laitinen, E., Ahola, H., Tenhunen, R., Taketani, S., and Mustajoki, P. 2001. Homozygous variegated porphyria: 20 y follow-up and characterization of molecular defect. *J. Invest. Dermatol.* 116:610-613.
- Kirsch, R.E., Meissner, P.N., and Hift, R.J. 1998. Variegated porphyria. *Semin. Liver Dis.* 18:33-41.
- Koszo, F., Elder, G.H., Roberts, A., and Simon, N. 1990. Uroporphyrinogen decarboxylase deficiency in hepatoerythropoietic porphyria: Further evidence of genetic heterogeneity. *Br. J. Dermatol.* 122:365-370.
- Kühnel, A., Gross, U., and Doss, M.O. 2000. Hereditary coproporphyria in Germany: Clinical-biochemical studies in 53 patients. *Clin. Biochem.* 33:465-473.
- Kuo, H.C., Huang, C.C., Chu, C.C., Lee, M.J., Chuang, W.L., Wu, C.L., Wu, T., Ning, H.C., and Liu, C.Y. 2011. Neurological complications of acute intermittent porphyria. *Eur. Neurol.* 66:247-252.
- Kushner, J.P., Barbuto, A.J., and Lee, G.R. 1976. An inherited enzymatic defect in porphyria cutanea tarda: Decreased uroporphyrinogen decarboxylase activity. *J. Clin. Invest.* 58:1089-1097.
- Lamoril, J., Boulechfar, S., de Verneuil, H., Grandchamp, B., Nordmann, Y., and Deybach, J.C. 1991. Human erythropoietic protoporphyria: Two point mutations in the ferrochelatase gene. *Biochem. Biophys. Res. Commun.* 181:594-599.
- Lamoril, J., Andant, C., Bogard, C., Puy, H., Gouya, L., Pawlotsky, J.M., Da Silva, V., Soulé, J.C., Deybach, J.C., and Nordmann, Y. 1998. Epidemiology of hepatitis C and G in sporadic and familial porphyria cutanea tarda. *Hepatology* 27:848-852.
- Langendonk, J.G., Balwani, M., Anderson, K.E., Bonkovsky, H.L., Anstey, A.V., Bissell, D.M., Bloomer, J.R., Edwards, C., Neumann, N.J., Parker, C., Phillips, J., Lim, H.W., Hamzavi, I., Deybach, J.-C., Kauppinen, R., Rhodes, L.E., Frank, J., Murphy, G.M., Karstens, F.P.J., Si-jbrands, E.J.G., de Rooij, F.W.M., Lebowohl, M., Naik, H., Goding, C.R., Wilson, J.H.P., and Desnick, R.J. 2015. Afamelanotide for erythropoietic protoporphyria. *N. Engl. J. Med.* In press.
- Lazaro, P., de Slamanca, R.E., Elder, G.H., Villaseca, M.L., Chinarro, S., and Jaqueti, G. 1984. Is hepatoerythropoietic porphyria a homozygous form of porphyria cutanea tarda? Inheritance of uroporphyrinogen decarboxylase deficiency in a Spanish family. *Br. J. Dermatol.* 110:613-617.
- Lee, J.S. and Anvret, M. 1991. Identification of the most common mutation within the porphobilinogen deaminase gene in Swedish patients with acute intermittent porphyria. *Proc. Natl. Acad. Sci. U.S.A.* 8:10912-10915.
- Lee, D.S., Flachsová, E., Bodnárová, M., Demeler, B., Martásek, P., and Raman, C.S. 2005. Structural basis of hereditary coproporphyria. *Proc. Natl. Acad. Sci. U.S.A.* 102:14232-14237.
- Lim, H.W. 1989. Pathophysiology of cutaneous lesions in porphyrias. *Semin. Hematol.* 26:114-119.
- Lim, H.W. and Poh-Fitzpatrick, M.B. 1984. Hepatoerythropoietic porphyria: A variant of childhood-onset porphyria cutanea tarda. Porphyrin profiles and enzymatic studies of two cases in a family. *J. Am. Acad. Dermatol.* 11:1103-1111.

- Lindblad, B., Lindstedt, S., and Steen, G. 1977. On the enzymic defects in hereditary tyrosinemia. *Proc. Natl. Acad. Sci. U.S.A.* 74:4641-4645.
- Lundvall, O. 1971. The effect of replenishment of iron stores after phlebotomy therapy in porphyria cutanea tarda. *Acta Med. Scand.* 189:51-63.
- Macalpine, I. and Hunter, R. 1966. The "insanity" of King George 3rd: A classic case of porphyria. *Br. Med. J.* 1:65-71.
- Magnus, I.A., Jarrett, A., Prankerd, T.A.J., and Rimington, C. 1961. Erythropoietic protoporphyria: A new porphyria syndrome with solar urticaria due to protoporphyrinaemia. *Lancet* 2:448-451.
- Mansourati, F.F., Stone, V.E., and Mayer, K.H. 1999. Porphyria cutanea tarda and HIV/AIDS. A review of pathogenesis, clinical manifestations and management. *Int. J. STD AIDS* 10:51-56.
- Maruno, M., Furuyama, K., Akagi, R., Horie, Y., Meguro, K., Garbaczewski, L., Chiorazzi, N., Doss, M.O., Hassoun, A., Mercelis, R., Verstraeten, L., Harper, P., Floderus, Y., Thunell, S., and Sassa S. 2001. Highly heterogeneous nature of δ -aminolevulinic acid dehydratase (ALAD) deficiencies in ALAD porphyria. *Blood* 97:2972-2978.
- McAlister, F., McClean, K., Hamilton, P.G., and Houston, S. 1995. Human immunodeficiency virus infection and porphyria cutanea tarda: Co-existence of risk factors or causative association? *Clin. Infect. Dis.* 20:348-351.
- McColl, K.E., Moore, M.R., Thompson, G.G., and Goldberg, A. 1981. Abnormal haem biosynthesis in chronic alcoholics. *Eur. J. Clin. Invest.* 11:461-468.
- McGuire, B.M., Bonkovsky, H.L., Carithers, R.L. Jr., Chung, R.T., Goldstein, L.I., Lake, J.R., Lok, A.S., Potter, C.J., Rand, E., Voigt, M.D., Davis, P.R., and Bloomer, J.R. 2005. Liver transplantation for erythropoietic protoporphyria liver disease. *Liver Transpl.* 11:1590-1596.
- McManus, J.F., Begley, C.G., Sassa, S., and Ratnaike, S. 1996. Five new mutations in the uroporphyrinogen decarboxylase gene identified in families with cutaneous porphyria. *Blood* 88:3589-3600.
- Meguro, K., Fujita, H., Ishida, N., Akagi, R., Kurihara, T., Galbraith, R.A., Kappas, A., Zabriskie, J.B., Toback, A.C., Harber, L.C., and Sassa, S. 1994. Molecular defects of uroporphyrinogen decarboxylase in a patient with mild hepatoerythropoietic porphyria. *J. Invest. Dermatol.* 102:681-685.
- Mehrany, K., Drage, L.A., Brandhagen, D.J., and Pittelkow, M.R. 2004. Association of porphyria cutanea tarda with hereditary hemochromatosis. *J. Am. Acad. Dermatol.* 51:205-211.
- Meissner, P.N., Dailey, T.A., Hift, R.J., Ziman, M., Corrigan, A.V., Roberts, A.G., Meissner, D.M., Kirsch, R.E., and Dailey, H.A. 1996. A 59W mutation in human protoporphyrinogen oxidase results in decreased enzyme activity and is prevalent in South Africans with variegate porphyria. *Nat. Genet.* 13:95-97.
- Meissner, P., Hift, R.J., and Corrigan, A. 2003. Variegate porphyria. In *Porphyria Handbook, Part II* (K.M. Kadish, K. Smith, and R. Guillard, eds.) p. 93. Academic Press, San Diego.
- Meissner, P.N., Corrigan, A.V., and Hift, R.J. 2012. Fifty years of porphyria at the University of Cape Town. *S. Afr. Med. J.* 102:422-426.
- Mendez, M., Sorkin, L., Rossetti, M.V., Astrin, K.H., del C Batlle, A.M., Parera, V.E., Aizencang, G., and Desnick, R.J. 1998. Familial porphyria cutanea tarda: Characterization of seven novel uroporphyrinogen decarboxylase mutations and frequency of hemochromatosis alleles. *Am. J. Hum. Genet.* 63:1363-1375.
- Minder, E.I. 2010. Afamelanotide, an agonistic analog of α -melanocyte-stimulating hormone, in dermal phototoxicity of erythropoietic protoporphyria. *Exp. Opin. Invest. Drugs* 19:1591-1602.
- Moran, M.J., Fontanellas, A., Brudieux, E., Hombrados, I., de Ledinghen, V., Couzigou, P., de Verneuil, H., and De Salamanca, R.E. 1998. Hepatic uroporphyrinogen decarboxylase activity in porphyria cutanea tarda patients: The influence of virus C infection. *Hepatology* 27:584-589.
- Moran-Jimenez, M.J., Ged, C., Romana, M., Enriquez de Salamanca, R., Taieb, A., Topi, G., Alessandro, L.D., and de Verneuil, H. 1996. Uroporphyrinogen decarboxylase: Complete human gene sequence and molecular study of three families with hepatoerythropoietic porphyria. *Am. J. Hum. Genet.* 58:712-721.
- Mukerji, S.K., Pimstone, N.R., and Burns M. 1984. Dual mechanism of inhibition of rat liver uroporphyrinogen decarboxylase activity by ferrous iron: Its potential role in the genesis of porphyria cutanea tarda. *Gastroenterology* 87:1248-1254.
- Murphy, A., Gibson, G., Elder, G.H., Otridge, B.A., and Murphy, G.M. 1995. Adult-onset congenital erythropoietic porphyria (Gunther's disease) presenting with thrombocytopenia. *J. R. Soc. Med.* 88:357P-358P.
- Mustajoki, P. 1980. Variegate porphyria. Twelve years' experience in Finland. *Q. J. Med.* 49:191-203.
- Nordmann, Y. and Puy, H. 2002. Human hereditary porphyrias. *Clin. Chim. Acta* 325:17-37.
- Nordmann, Y., Puy, H., Da Silva, V., Simonin, S., Robreau, A.M., Bonaiti, C., Phung, L.N., and Deybach, J.C. 1997. Acute intermittent porphyria: Prevalence of mutations in the porphobilinogen deaminase gene in blood donors in France. *J. Intern. Med.* 242:213-217.
- Norris, P.G., Nunn, A.V., Hawk, J.L.M., and Cox, T.M. 1991. Genetic heterogeneity in erythropoietic protoporphyria: A study of the enzyme defect in nine affected families. *J. Invest. Dermatol.* 95:260-263.
- O'Connor, W.J., Murphy, G.M., Darby, C., Fogarty, J., Mulcahy, F., O'Moore, R., and Barnes, L. 1996. Porphyrin abnormalities in acquired immunodeficiency syndrome. *Arch. Dermatol.* 132:1443-1447.

- Oliver, R.M. 1975. Toxic effects of 2,3,7,8 tetrachlorodibenzo-1,4-dioxin in laboratory workers. *Br. J. Indust. Med.* 32:49-53.
- O'Reilly, F.M., Darby, C., Fogarty, J., O'Moore, R., Courtney, M.G., O'Connor, J., Kay, E.W., Leader, M., Fielding, J.F., and Murphy, G.M. 1996. Porphyrin metabolism in hepatitis C infection. *Photodermatol. Photoimmunol. Photomed.* 12:31-33.
- Parsons, J.L., Sahn, E.E., Holden, K.R., and Pai, G.S. 1994. Neurologic disease in a child with hepatoerythropoietic porphyria. *Pediatr. Dermatol.* 11:216-221.
- Pawlotsky, J.M., Dhumeaux, D., and Bagot, M. 1995. Hepatitis C virus in dermatology. A review. *Arch. Dermatol.* 131:1185-1193.
- Pazderova-Vejlupková, J., Nemcova, M., Pícková, J., Jirásek, L., and Lukás, E. 1981. The development and prognosis of chronic intoxication by tetrachlorodibenzo-*p*-dioxin in men. *Arch. Environ. Health* 36:5-11.
- Peters, T. 2009. Thomas Wakley, King George III and acute porphyria. *J. R. Soc. Med.* 102:506.
- Phillips, J.D. and Kushner, J.P. 2005. Fast track to the porphyrias. *Nat. Med.* 11:1049-1050.
- Phillips, J.D., Bergonia, H.A., Reilly, C.A., Franklin, M.R., and Kushner, J.P. 2007a. A porphomethene inhibitor of uroporphyrinogen decarboxylase causes porphyria cutanea tarda. *Proc. Natl. Acad. Sci. U.S.A.* 104:5079-5084.
- Phillips, J.D., Steensma, D.P., Pulsipher, M.A., Spangrude, G.J., and Kushner, J.P. 2007b. Congenital erythropoietic porphyria due to a mutation in GATA1: The first trans-acting mutation causative for a human porphyria. *Blood* 109:2618-2621.
- Phillips, J.D., Whitby, F.G., Stadtmueller, B.M., Edwards, C.Q., Hill, C.P., and Kushner, J.P. 2007c. Two novel uroporphyrinogen decarboxylase (URO-D) mutations causing hepatoerythropoietic porphyria (HEP). *Transl. Res.* 149:85-91.
- Pischik, E. and Kauppinen, R. 2009. Neurological manifestations of acute intermittent porphyria. *Cell Mol. Biol.* 55:72-83.
- Poh-Fitzpatrick, M.B. 1995. Porphyrias. In *Cutaneous Medicine and Surgery: An Integrated Program in Dermatology* (K.A. Arndt, P.E. LeBoit, J.K. Robinson, and B.U. Wintroub, eds.) pp. 1753-1762. W.B. Saunders, Philadelphia.
- Potluri, V.R., Astrin, K.H., Wetmur, J.G., Bishop, D.F., and Desnick, R.J. 1987. Human δ -aminolevulinic acid dehydratase: Chromosomal localization to 9q34 by in situ hybridization. *Hum. Genet.* 6:236-239.
- Puy, H., Gouya, L., and Deybach, J.C. 2010. Porphyrias. *Lancet* 375:924-937.
- Rank, J.M., Pascual-Leone, A., Payne, W., Glock, M., Freese, D., Sharp, H., and Bloomer, J.R. 1991. Hematin therapy for the neurologic crisis of tyrosinemia. *J. Pediatr.* 118:136-139.
- Remenyik, E., Lecha, M., Badenas, C., Kószó, F., Vass, V., Herrero, C., Varga, V., Emri, G., Balogh, A., and Horkay, I. 2008. Childhood-onset mild cutaneous porphyria with compound heterozygotic mutations in the uroporphyrinogen decarboxylase gene. *Clin. Exp. Dermatol.* 33:602-605.
- Roberts, A.G., Elder, G.H., de Salamanca, R.E., Herrero, C., Lecha, M., and Mascaro, J.M. 1995. A mutation (G281E) of the human uroporphyrinogen decarboxylase gene causes both hepatoerythropoietic porphyria and overt familial porphyria cutanea tarda: Biochemical and genetic studies on Spanish patients. *J. Invest. Dermatol.* 104:500-502.
- Roberts, A.G., Whatley, S.D., Morgan, R.R., Woodward, M., and Elder, G.H. 1997. Increased frequency of the haemochromatosis Cys282Tyr mutation in sporadic porphyria cutanea tarda. *Lancet* 349:321-323.
- Rocchi, E., Gibertini, P., Cassanelli, M., Pietrangelo, A., Jensen, J., and Ventura E. 1986. Hepatitis B virus infection in porphyria cutanea tarda. *Liver* 6:153-157.
- Romeo, G. and Levin, E.Y. 1969. Uroporphyrinogen 3 cosynthetase in human congenital erythropoietic porphyria. *Proc. Natl. Acad. Sci. U.S.A.* 63:856-863.
- Romeo, G., Kaback, M.M., and Levin, E.Y. 1970. Uroporphyrinogen 3 cosynthetase activity in fibroblasts from patients with congenital erythropoietic porphyria. *Biochem. Genet.* 4:659-664.
- Roméo, P.H., Raich, N., Dubart, A., Beaupain, D., Pryor, M., Kushner, J., Cohen-Solal, M., and Goossens, M. 1986. Molecular cloning and nucleotide sequence of a complete human uroporphyrinogen decarboxylase cDNA. *J. Biol. Chem.* 261:9825-9831.
- Rosipal, R., Lamoril, J., Puy, H., Da Silva, V., Gouya, L., De Rooij, F.W., Te Velde, K., Nordmann, Y., Martásek P, and Deybach, J.C. 1999. Systematic analysis of coproporphyrinogen oxidase gene defects in hereditary coproporphyrin and mutation update. *Hum. Mutat.* 13:44-53.
- Sampietro, M., Piperno, A., Lupica, L., Arosio, C., Vergani, A., Corbetta, N., Malosio, I., Mattioli, M., Fracanzani, A.L., Cappellini, M.D., Fiorelli, G., and Fargion, S. 1998. High prevalence of the His63Asp HFE mutation in Italian patients with porphyria cutanea tarda. *Hepatology* 27:181-184.
- Sampietro, M., Fiorelli, G., and Fargion, S. 1999. Iron overload in porphyria cutanea tarda. *Haematologica* 84:248-253.
- Samuel, D., Boboc, B., Bernuau, J., Bismuth, H., and Benhamou, J.P. 1988. Liver transplantation for protoporphyria. Evidence for the predominant role of the erythropoietic tissue in protoporphyria overproduction. *Gastroenterology* 95:816-819.
- Santos, M., Clevers, H.C., and Marx, J.J. 1997. Mutations of the hereditary hemochromatosis candidate gene HLA-H in porphyria cutanea tarda. *N. Engl. J. Med.* 336:1327-1328.

- Sarkany, R.P.E. 2001. The management of porphyria cutanea tarda. *Clin. Exp. Dermatol.* 26:225-232.
- Sarkany, R.P.E. 2008. Making sense of the porphyrias. *Photodermatol. Photoimmunol. Photomed.* 24:102-108.
- Sarkany, R.P.E. and Cox, T.M. 1995. Autosomal recessive erythropoietic protoporphyria: A syndrome of severe photosensitivity and liver failure. *Q. J. Med.* 88:541-549.
- Sarkany, R.P.E., Alexander, G.J.M.A., and Cox, T.M. 1994. Recessive inheritance of erythropoietic protoporphyria with liver failure. *Lancet* 343:1394-1395.
- Sassa, S. 1982. δ -Aminolevulinic acid dehydratase assay. *Enzyme* 28:133-145.
- Sassa, S. 1998. ALAD porphyria. *Semin. Liver Dis.* 18:95-101.
- Sassa, S. 2006. Modern diagnosis and management of the porphyrias. *Br. J. Haematol.* 135:281-292.
- Sassa, S. and Kappas, A. 1983. Hereditary tyrosinemia and the heme biosynthetic pathway: Profound inhibition of δ -aminolevulinic acid dehydratase activity by succinylacetone. *J. Clin. Invest.* 71:625-634.
- Sassa, S., Granick, S., and Kappas, A. 1975. Effect of lead and genetic factors on heme biosynthesis in the human red cell. *Ann. N.Y. Acad. Sci.* 244:419-440.
- Schmid, R. 1960. Cutaneous porphyria in Turkey. *N. Engl. J. Med.* 263:397-398.
- Schmitt, C., Gouya, L., Malonova, E., Lamoril, J., Camadro, J.M., Flamme, M., Rose, C., Lyoumi, S., Da Silva, V., Boileau, C., Grandchamp, B., Beaumont, C., Deybach, J.C., and Puy, H. 2005. Mutations in human CPO gene predict clinical expression of either hepatic hereditary coproporphyria or erythropoietic harderoporphyria. *Hum. Mol. Genet.* 4:3089-3098.
- Scinicariello, F., Murray, H.E., Moffett, D.B., Abadin, H.G., Sexton, M.J., and Fowler, B.A. 2007. Lead and δ -aminolevulinic acid dehydratase polymorphism: Where does it lead? A meta-analysis. *Env. Health Perspect.* 115:35-41.
- Sepkowitz, D.V., Hennessey, P., Torno, R.B., and Lampert, M.A. 1995. Hepatic manifestations of porphyria cutanea tarda in a patient with AIDS. *Am. J. Gastroenterol.* 90:658-659.
- Shady, A.A., Colby, B.R., Cunha, L.F., Astrin, K.H., Bishop, D.F., and Desnick, R.J. 2002. Congenital erythropoietic porphyria: Identification and expression of eight novel mutations in the uroporphyrinogen III synthase gene. *Br. J. Haematol.* 117:980-998.
- Siersema, P.D., Rademakers, L.H., Cleton, M.I., ten Kate, F.J., de Bruijn, W.C., Marx, J.J., and Wilson, J.H. 1995. The difference in liver pathology between sporadic and familial forms of porphyria cutanea tarda: The role of iron. *J. Hepatol.* 23:259-267.
- Singal, A.K. and Anderson, K.E. 2013. Variegate porphyria. In: GeneReviews [Internet] (R.A. Pagon, M.P. Adam, H.H., Ardinger, et al., eds.). University of Washington, Seattle. <http://www.ncbi.nlm.nih.gov/books/NBK121283/>.
- Singal, A.H. and Phillips, J.D. 2014. Porphyria cutanea tarda. In Handbook of Porphyrin Science with Applications in Chemistry, Physics, Materials Science, Engineering, Biology, and Medicine, Vol. 29: Porphyrias and Sideroblastic Anemias (G.C. Ferreira, K.M. Kadish, K.M. Smith, and R. Guillard, eds.) pp. 219-261. World Scientific Publishing, Hackensack, N.J.
- Singal, A.K., Kormos-Hallberg, C., Lee, C., Sadagoparamanujam, V.M., Grady, J.J., Freeman, D.J., and Anderson, K.E. 2012. Low-dose hydroxychloroquine is as effective as phlebotomy in treatment of patients with porphyria cutanea tarda. *Clin. Gastroenterol. Hepatol.* 10:1402-1409.
- Smith, S.G. 1986. Hepatoerythropoietic porphyria. *Semin. Dermatol.* 5:125-137.
- Stockvis, B.J. 1989. Weekblad van het Nederlandsch Tijdschrift voor Geneeskunde. Second part, no. 13. About two unusual dyes in the urine of patients. *Ned. Tijdschr. Geneesk.* 133:2562-2570, PMID:2689889.
- Stuart, K.A., Busfield, F., Jazwinska, E.C., Gibson, P., Butterworth, L.A., Cooksley, W.G., Powell, L.W., and Crawford, D.H. 1998. The C282Y mutation in the haemochromatosis gene (HFE) and hepatitis C virus infection are independent cofactors for porphyria cutanea tarda in Australian patients. *J. Hepatol.* 28:404-409.
- Sweeney, G.D. 1986. Porphyria cutanea tarda, or the uroporphyrinogen decarboxylase deficiency diseases. *Clin. Biochem.* 19:3-15.
- Tanigawa, K., Takamura, N., and Yamashita, S. 1995. Congenital erythropoietic porphyria. *Nihon Rinsho* 53:1422-1426.
- Thunell, S. and Harper, P. 2000. Porphyrins, porphyrin metabolism, porphyrias. III. Diagnosis, care and monitoring in porphyria cutanea tarda—suggestions for a handling programme. *Scand. J. Clin. Lab. Invest.* 60:561-579.
- Thunell, S., Holmberg L., and Lundgren, J. 1987. Aminolaevulinic acid dehydratase porphyria in infancy. A clinical and biochemical study. *J. Clin. Chem. Clin. Biochem.* 25:5-14.
- Thunell, S., Pomp, E., and Brun, A. 2007. Guide to drug porphyrinogenicity prediction and drug prescription in the acute porphyrias. *Br. J. Clin. Pharm.* 64:668-679.
- Todd, D.J. 1994. Review: Erythropoietic protoporphyria. *Br. J. Dermatol.* 131:751-766.
- To-Figueras, J., Ducamp, S., Clayton, J., Badenas, C., Delaby, C., Ged, C., Lyoumi, S., Gouya, L., de Verneuil, H., Beaumont, C., Ferreira, G.C., Deybach, J.C., Herrero, C., and Puy, H. 2011. ALAS2 acts as a modifier gene in patients with congenital erythropoietic porphyria. *Blood* 118:1443-1451.
- Touart, D.M. and Sau, P. 1998. Cutaneous deposition diseases. Part I. *J. Am. Acad. Dermatol.* 39:149-171.

- Tschudy, D.P., Valsamis, M., and Magnussen, C.R. 1975. Acute intermittent porphyria: Clinical and selected research aspects. *Ann. Intern. Med.* 83:851-864.
- Tsukazaki, N., Watanabe, M., and Irifune, H. 1998. Porphyria cutanea tarda and hepatitis C virus infection. *Br. J. Dermatol.* 138:1015-1017.
- Verneuil, H., de Aitkne, G., and Nordmann, Y. 1978. Familial and sporadic porphyria cutanea tarda: Two different diseases. *Hum. Genet.* 44:45-51.
- Verneuil, H. de, Beaumont, C., Deybach, J.C., Nordmann, Y., Sfar, Z., and Kastally, R. 1984a. Enzymatic and immunological studies of uroporphyrinogen decarboxylase in familial porphyria cutanea tarda and hepatoerythropoietic porphyria. *Am. J. Hum. Genet.* 36:613-622.
- Verneuil, H. de, Grandchamp, B., Foubert, C., Weil, D., N'Guyen, V.C., Gross, M.S., Sassa, S., and Nordmann, Y. 1984b. Assignment of the gene for uroporphyrinogen decarboxylase to human chromosome 1 by somatic cell hybridization and specific enzyme immunoassay. *Hum. Genet.* 66:202-205.
- Verneuil, H. de, Grandchamp, B., Beaumont, C., Picat, C., and Nordmann, Y. 1986. Uroporphyrinogen decarboxylase structural mutant (Gly281—Glu) in a case of porphyria. *Science* 234:732-734.
- Verstraeten, L., Van Regemorter, N., Pardou, A., de Verneuil, H., Da Silva, V., Rodesch, F., et al. 1993. Biochemical diagnosis of a fatal case of Gunther's disease in a newborn with hydrops foetalis. *Eur. J. Clin. Chem. Clin. Biochem.* 31:121-128.
- von und zu Fraunberg, M., Timonen, K., Mustajoki, P., and Kauppinen, R. 2002. Clinical and biochemical characteristics and genotype-phenotype correlation in Finnish variegate porphyria patients. *Eur. J. Hum. Genet.* 10:649-657.
- Waldenstrom, J. 1957. The porphyrias as inborn errors of metabolism. *Am. J. Med.* 22:758-773.
- Warner, C.A., Poh-Fitzpatrick, M.B., Zaider, E.F., Tsai, S.F., and Desnick, R.J. 1992. Congenital erythropoietic porphyria. A mild variant with low uroporphyrin I levels due to a missense mutation (A66V) encoding residual uroporphyrinogen III synthase activity. *Arch. Dermatol.* 128:1243-1248.
- Warnich, L., Kotze, M.J., Groenewald, I.M., Groenewald, J.Z., van Brakel, M.G., van Heerden, C.J., de Villiers, J.N.P., van der Ven, W.J.M., Schoenmakers, E.F.P.M., Taketani, S., and Retief, A. 1996. Identification of three mutations and associated haplotypes in the protoporphyrinogen oxidase gene in South African families with variegate porphyria. *Hum. Mol. Genet.* 5:981-984.
- Went, L.N. and Klasen, E.C. 1984. Genetic aspects of erythropoietic protoporphyria. *Ann. Hum. Genet.* 48:105-117.
- Wetmur, J.G., Bishop, D.F., Ostasiewicz, L., and Desnick, R.J. 1986. Molecular cloning of a cDNA for human δ -aminolevulinate dehydratase. *Gene* 43:123-130.
- Wetmur, J.G., Kaya, A.H., Plewiska, M., and Desnick, R.J. 1991. Molecular characterization of the human δ -aminolevulinate dehydratase 2 (ALAD2) allele: Implications for molecular screening of individuals for genetic susceptibility to lead poisoning. *Am. J. Hum. Genet.* 49:757-763.
- Whatley, S.D. and Badminton, M.N. 2005. Acute intermittent porphyria. In: GeneReviews (Internet) (R.A. Pagon, M.P. Adam, H.H. Ardinger, et al., eds.). University of Washington, Seattle. <http://www.ncbi.nlm.nih.gov/books/NBK1193/>
- Whatley, S.D. and Badminton, M.N. 2013. Role of genetic testing in the management of patients with inherited porphyria and their families. *Ann. Clin. Biochem.* 50:204-216.
- Whatley, S.D., Puy, H., Morgan, R.R., Robreau, A.M., Roberts, A.G., Nordmann, Y., Elder, G.H., and Deyback, J.C. 1999. Variegate porphyria in Western Europe: Identification of PPOX gene mutations in 104 families, extent of allelic heterogeneity, and absence of correlation between phenotype and type of mutation. *Am. J. Hum. Genet.* 65:984-994.
- Whatley, S.D., Ducamp, S., Gouya, L., Grandchamp, B., Beaumont, C., Badminton, M.N., Elder, G.H., Holme, S.A., Anstey, A.V., Parker, M., Corrigan, A.V., Meissner, P.N., Hift, R.J., Marsden, J.T., Ma, Y., Mieli-Vergani, G., Deyback, J.C., and Puy H. 2008. C-terminal deletions in the ALAS2 gene lead to gain of function and cause X-linked dominant protoporphyria without anemia or iron overload. *Am. J. Hum. Genet.* 83:408-414.
- Whatley, S.D., Mason, N.G., Woolf, J.R., Newcombe, R.G., Elder, G.H., and Badminton, M.N. 2009. Diagnostic strategies for autosomal dominant acute porphyrias: Retrospective analysis of 467 unrelated patients referred for mutational analysis of the HMBS, CPOX, or PPOX gene. *Clin. Chem.* 55:1406-1414.
- Whatley, S.D., Mason, N.G., Holme, S.A., Anstey, A.V., Elder, G.H., and Badminton, M.N. 2010. Molecular epidemiology of erythropoietic protoporphyria in the U.K. *Br. J. Dermatol.* 162:642-646.
- Wissel, P.S., Sordillo, P., Anderson, K.E., Sassa, S., Savillo, R.L., and Kappas, A. 1987. Porphyria cutanea tarda associated with the acquired immune deficiency syndrome. *Am. J. Hematol.* 25:107-113.
- Xu, W., Warner, C.A., and Desnick, R.J. 1995. Congenital erythropoietic porphyria: Identification and expression of 10 mutations in the uroporphyrinogen III synthase gene. *J. Clin. Invest.* 95:905-912.