

# Guidelines on the diagnosis and management of thrombotic thrombocytopenic purpura and other thrombotic microangiopathies

Marie Scully,<sup>1</sup> Beverley J. Hunt,<sup>2</sup> Sylvia Benjamin,<sup>3</sup> Ri Liesner,<sup>4</sup> Peter Rose,<sup>5</sup> Flora Peyvandi,<sup>6</sup> Betty Cheung<sup>7</sup> and Samuel J. Machin<sup>8</sup> on behalf of British Committee for Standards in Haematology

<sup>1</sup>Department of Haematology, UCLH, London, <sup>2</sup>Department of Haematology, King's College and Guys & St Thomas' NHS Trust, London, <sup>3</sup>Department of Haematology, NBSBT and Oxford University Hospitals (OUH) Trust, UK, <sup>4</sup>Department of Haematology, GOSH, London, <sup>5</sup>Department of Haematology, University Hospitals Coventry & Warwickshire NHS trust, Coventry, UK, <sup>6</sup>Department of Haematology, IRCCS Maggiore Hospital Ca' Granda Foundation, University of Milan, Milan, Italy, <sup>7</sup>Department of Haematology, Queen Elizabeth Hospital, SLHT, London and <sup>8</sup>Department of Haematology, UCL, London, UK

**Keywords:** thrombotic thrombocytopenic purpura, thrombotic microangiopathy, guidelines.

The guideline group was selected to be representative of UK-based medical experts. MEDLINE and EMBASE were searched systematically for publications in English, using the keywords: thrombotic thrombocytopenia purpura (TTP), ADAMTS13, plasma exchange (PEX) and relevant key words related to the subsections of this guideline. The writing group produced the draft guideline, which was subsequently revised by consensus by members of the Haemostasis and Thrombosis Task Force of the BCSH. The guideline was then reviewed by a sounding board of British haematologists, the BCSH and the British Society for Haematology Committee and comments incorporated where appropriate. The 'GRADE' system was used to quote levels and grades of evidence, details of which can be found at <http://www.bcsghguidelines.com>.

The objective of this guideline is to provide healthcare professionals with clear, up-to-date, and practical guidance on the management of TTP and related thrombotic microangiopathies, defined by thrombocytopenia, microangiopathic haemolytic anaemia (MAHA) and small vessel thrombosis.

## Pathogenesis

Thrombotic thrombocytopenic purpura (TTP) is rare, with a reported incidence of six cases per million per year in the UK (Scully *et al*, 2008). It is an important diagnosis to make because the untreated mortality is 90%, which can be reduced with the prompt delivery of plasma exchange (PEX). Early death still occurs: approximately half of the deaths in

the regional UK registry occurred within 24 h of presentation, primarily in women (Scully *et al*, 2008).

In the last 15 years there has been a marked increase in the understanding of the pathogenesis of TTP. It is now recognized that congenital and acute acquired TTP are due to a deficiency of von Willebrand factor (VWF) cleaving protein, also known as ADAMTS1, (a disintegrin and metalloproteinase with a thrombospondin type 1 motif, member 13 – von Willebrand factor cleaving protein) (Fujikawa *et al*, 2001; Levy *et al*, 2001). In the absence of ADAMTS13, ultra large multimers of VWF (ULVWF) released from endothelium are not cleaved appropriately, and cause spontaneous platelet aggregates in conditions of high shear, such as in the microvasculature of the brain, heart and kidneys.

Congenital TTP is due to an inherited deficiency of ADAMTS13, but acquired immune TTP is due to the reduction of ADAMTS13 by autoantibodies directed against ADAMTS13 (Furlan *et al*, 1998a; Tsai & Lian, 1998). Other clinical forms of thrombotic microangiopathy (TMA) occur in the absence of severe deficiency.

Diagnosis can be difficult, as there is clinical overlap with haemolytic uraemic syndrome (HUS), autoimmune disease and a spectrum of pregnancy-related problems.

## Diagnosis of TTP

Thrombotic thrombocytopenic purpura was originally characterized by a pentad of thrombocytopenia, MAHA, fluctuating neurological signs, renal impairment and fever, often with insidious onset. However, TTP can present without the full pentad; up to 35% of patients do not have neurological signs at presentation and renal abnormalities and fever are not prominent features. The revised diagnostic criteria state that TTP must be considered in the presence of thrombocytopenia and MAHA alone (Galbusera *et al*, 2006). This can result in an increased referral of other TMAs (Table 1). TTP remains a

Correspondence: Dr M Scully, BCSH Secretary, British Society for Haematology, 100 White Lion Street, London N1 9PF, UK.  
E-mail [bcsgh@b-s-h.org.uk](mailto:bcsgh@b-s-h.org.uk)

**Table I.** Differential diagnosis of thrombocytopenia and microangiopathic haemolytic anaemia.

Autoimmune haemolysis/Evans syndrome
Disseminated intravascular coagulation
Pregnancy-associated e.g. HELLP (haemolysis, elevated liver enzymes and low platelets), eclampsia, haemolytic uraemic syndrome
Drugs eg quinine, simvastatin, interferon, Calcineurin inhibitors
Malignant hypertension
Infections, typically viral (cytomegalovirus, adenovirus, herpes simplex virus) or severe bacterial (meningococcus, pneumococcus), fungal
Autoimmune disease (lupus nephritis, acute scleroderma)
Vasculitis
Haemolytic uraemic syndrome (diarrhoea positive/negative)
Malignancy
Catastrophic antiphospholipid syndrome

**Table II.** Presenting clinical features and signs in acute TTP.

Thrombocytopenia	Epistaxis, bruising, petechiae, gingival bleeding, haematuria, menorrhagia, gastrointestinal bleeding, retinal haemorrhage and haemoptysis
Central neurological – often flitting and variable 70–80%	Confusion, headache, paresis, aphasia, dysarthria, visual problems, encephalopathy, coma (10%)
Fever (>37.5°C)	
Non-specific symptoms	Pallor, jaundice, fatigue, arthralgia or myalgia
Jaundice	Resulting from microangiopathic haemolytic anaemia
Renal Impairment	Proteinuria, microhaematuria
Cardiac	Chest pain, heart failure, hypotension
Gastro-intestinal tract	Abdominal pain

diagnosis based on clinical history, examination of the patient and the blood film. ADAMTS 13 assays help to confirm the diagnosis and monitor the course of the disease and possible need for additional treatments.

Presenting symptoms and signs are summarized in Table II and reflect widespread multi organ thromboses. Neurological impairment has multiple presentations including headache, altered personality, reduced cognition, transient ischaemic attacks, fits and fluctuating levels of consciousness including coma; the latter is a poor prognostic sign. Acute renal failure requiring haemodialysis is rare in TTP and more indicative of HUS (Coppo *et al*, 2006; Scully *et al*, 2008). Additional ischaemic complications may be seen, such as abdominal pain due to intestinal ischaemia.

Consumption of platelets in platelet-rich thrombi results in thrombocytopenia. The median platelet count is typically  $10\text{--}30 \times 10^9/\text{l}$  at presentation (Dervenoulas *et al*, 2000; Vesely *et al*, 2003; Coppo *et al*, 2006; Tuncer *et al*, 2007; Scully *et al*, 2008). Mechanical fragmentation of erythrocytes during flow through partially occluded, high shear small vessels causes a MAHA. Median haemoglobin levels on admission are typically 80–100 g/l, with schistocytes in the

film, low haptoglobin levels and raised reticulocyte counts due to haemolysis. The direct Coombs test is negative. The combination of haemolysis and tissue ischaemia produces elevated lactate dehydrogenase (LDH) values.

The clotting screen (prothrombin time, activated partial thromboplastin time and fibrinogen) is usually normal. A virology screen pre-treatment is necessary to exclude human immunodeficiency virus (HIV) and other viral-associated TTP, and as a baseline prior to plasma exposure. Troponin T levels are raised in 50% of acute idiopathic TTP cases (Hughes *et al*, 2009), highlighting that cardiac involvement is common. Raised troponin levels are a sinister finding, for coronary artery occlusion is a common mode of early death. The incidence of symptomatic heart failure is increased in patients who have been given a recent platelet transfusion (Gami *et al*, 2005) (Table III).

#### ADAMTS13 assays

Blood must be taken prior to treatment to assess baseline ADAMTS13 activity. Severely reduced ADAMTS13 activity (<5%) ± the presence of an inhibitor or IgG antibodies, confirms the diagnosis (Peyvandi *et al*, 2004; Coppo *et al*, 2006; Ferrari *et al*, 2007; Scully *et al*, 2007a). Decreased ADAMTS13 activity (<40% but >5%) has been reported in a wide variety of non-TTP conditions such as uraemia, inflammatory states, post-operatively and during pregnancy (Loof *et al*, 2001; Mannucci *et al*, 2001; Moore *et al*, 2001). The specificity of severe ADAMTS13 deficiency (<5%) in distinguishing acute TTP from HUS is 90% (Bianchi *et al*, 2002; Zheng *et al*, 2004).

ADAMTS13 assays currently available include assays of activity, antigen and neutralizing or non-neutralizing anti-ADAMTS13 autoantibodies. Functional assays measuring ADAMTS13 activity are based on the failure of the patient plasma to degrade VWF multimers or synthetic VWF peptides. Inhibitory autoantibodies can be titrated *in vitro* using classical mixing studies and non-neutralizing antibodies can be detected by Western blotting or enzyme-linked immunosorbent assays (Peyvandi *et al*, 2010).

#### Recommendation

- 1 The diagnosis of TTP should be treated as a medical emergency (1A).**
- 2 The initial diagnosis of TTP should be made on clinical history, examination and routine laboratory parameters of the patient, including blood film review (1A).**
- 3 In view of the high risk of preventable, early deaths in TTP, treatment with PEX should be initiated as soon as possible, preferably within 4–8 h, regardless of the time of day at presentation, if a patient presents with a MAHA and thrombocytopenia in the absence of any other identifiable clinical cause (1B).**
- 4 Serological tests for HIV, hepatitis B virus and hepatitis C virus, autoantibody screen and when appropriate, a pregnancy test, should be performed at presentation (1A).**

**Table III.** Testing and expected results for patients with a suspected diagnosis of TTP. Blood samples should be sent for investigation before first PEX.

For diagnosis	
Full blood count and blood film	Anaemia, thrombocytopenia, fragments on film
Reticulocyte count	Raised
Haptoglobin	Reduced
Clotting screen including fibrinogen	Normal
Urea and electrolytes	Renal impairment
Troponin T/Troponin I	For cardiac involvement
Liver function tests	Usually normal
Calcium	May reduce with PEX
Lactate dehydrogenase	Raised due to haemolysis
Urinalysis	For protein
Direct antiglobulin test	Negative
Blood group and antibody screen	To allow provision of blood products
Hepatitis A/B/C and human immunodeficiency virus testing	Pre-blood products and to exclude an underlying viral precipitant
Pregnancy test (in women of child-bearing age)	
ADAMTS 13 assay (activity/antigen and inhibitor/antibody in specialized laboratory)	Do not wait for result before starting treatment in suspected TTP
Electrocardiogram/Echocardiogram	To document/monitor cardiac damage
CT/MRI brain	To determine neurological involvement*
For possible underlying cause	
Thyroid function tests	To exclude Graves Disease
Auto-antibody screen (ANA/RF/LA/ACLA), including lupus anticoagulant	Exclude associated autoimmune disease
Stool culture	For pathogenic <i>Escherichia coli</i> (if diarrhoea)
CT Chest/abdomen/pelvis (if indicated) ± tumour markers	To look for underlying malignancy

PEX, plasma exchange; CT, computerized tomography; MRI, magnetic resonance imaging; ANA, antinuclear antibody; RF, rheumatoid factor; LA, lupus antibody; ACLA, anticardiolipin antibodies; TTP, thrombotic thrombocytopenia purpura.

\*Brain scanning on admission should not interrupt PEX therapy.

**5 Pre-treatment samples should be obtained to measure ADAMTS13 activity levels and to detect anti-ADAMTS13 antibodies. Measurement of ADAMTS 13 antigen levels is also useful in congenital TTP cases (1B).**

## Subgroups of TTP

### Congenital TTP

Congenital TTP is a rare disorder, with over 100 patients described worldwide, but this is likely to be an underestimate. It has a varied phenotype and can present at any age. As a general rule, those with more severe phenotypes present early:

**1** Neonates typically have severe neonatal jaundice. Blood film examination may show schistocytes together with red cell anisocytosis. (Scully *et al*, 2006a).

**2** More frequently, the diagnosis is made later in infancy or childhood (Schiff *et al*, 2004), typically with thrombocytopenia, MAHA, jaundice and elevated LDH, although some children may only have an isolated thrombocytopenia. Neurological symptoms, such as hemiparesis, hemiplegia or seizures, occur in 35% of cases (Loirat *et al*, 2006).

**3** Patients may present in adulthood. In women, pregnancy is a common precipitant and is associated with a significant neonatal morbidity and mortality (Fujimura *et al*, 2009). Rarely 'late-onset phenotype' cases may not develop symptoms until their 50s and 60s with isolated cerebral events or renal disease ((Fujimura *et al*, 2011). Asymptomatic male cases have been reported, usually detected because they have affected siblings.

Patients with congenital TTP have persistently low levels of ADAMTS13, but they can be asymptomatic until a further precipitating event results in a frank TTP episode. Events include febrile episodes, infections, vaccinations, excess alcohol intake and pregnancy (Furlan *et al*, 1997, 1998b; Schneppenheim *et al*, 2003).

Congenital TTP has been missed in the past, because the diagnosis has not been considered, or diagnosed as idiopathic thrombocytopenic purpura or 'atypical' HUS (Veyradier *et al*, 2003), illustrating the importance of consideration of the diagnosis, review of the blood film and measurement of ADAMTS13.

The diagnosis of congenital TTP is dependent on detecting ADAMTS13 activity <5%, in the absence of antibodies to ADAMTS13. In the last few years molecular diagnosis has been used to confirm the diagnosis, and either a homozygous or compound heterozygote defect in *ADAMTS13* is found. Testing of siblings and other first-degree relatives at risk should be considered.

### Recommendations

- 1 Congenital TTP should be considered in neonates presenting with severe jaundice. Presentation may also occur in childhood or as an adult (1A).**
- 2 The diagnosis of congenital TTP should be considered in children and adults with unexplained thrombocytopenia (1B).**
- 3 The diagnosis of congenital TTP is confirmed by ADAMTS13 activity <5%, absence of antibody and confirmation of homozygous or compound heterozygous defects of the ADAMTS13 gene (1A).**

### Acute idiopathic TTP

Acute idiopathic TTP is the most common form of TTP. It is an autoimmune disease characterized by antibodies, usually IgG, directed against ADAMTS13. The incidence is

four to six cases per million of the population per year in the United States (Miller *et al*, 2004; Terrell *et al*, 2005) and six cases per million per year in the UK (Scully *et al*, 2008).

#### HIV-associated TTP

Thrombotic thrombocytopenia purpura may be the initial presenting feature of HIV disease or in those with low CD4 counts following non-compliance with antiviral treatment (Ucar *et al*, 1994; Gervasoni *et al*, 2002). Remission is dependent upon improving the immune status of the patient, for stopping highly active anti retroviral therapy (HAART) can result in acute TTP relapse (Miller *et al*, 2005), but continued use of HAART usually prevents further relapses. TTP in HIV-positive individuals may be associated with the presence of severe ADAMTS13 deficiency and anti-ADAMTS13 antibodies. Those with severe ADAMTS13 deficiency (<5%) have fewer acquired immunodeficiency syndrome-related complications and higher CD4+ T cell counts, compared to HIV-TTP with ADAMTS13 levels >5%, who have an increased mortality (Malak *et al*, 2008).

#### Pregnancy-associated TTP

Pregnancy can be the initiating event for approximately 5–25% of TTP cases (Ridolfi & Bell, 1981; Vesely *et al*, 2004; Scully *et al*, 2008), which are late onset adult congenital TTP or acute idiopathic TTP. Differentiating TTP from the more common pregnancy-related TMAs, such as pre-eclampsia, HELLP syndrome (haemolysis, elevated liver enzymes, low platelets) and HUS is difficult, especially if TTP presents post-partum (Table IV). Thrombosis occurs in the placenta in untreated TTP pregnancies and results in fetal growth restriction, intrauterine fetal death and pre eclampsia. There is a continued risk of relapse during subsequent pregnancies. Women with normal levels of ADAMTS13 pre-pregnancy have a lower risk of relapse (Ducloy-Bouthors *et al*, 2003; Scully *et al*, 2006b).

Table IV. Typical features in pregnancy-associated microangiopathies.

	MAHA	Thrombocytopenia	Coagulopathy	HBP	Abdominal symptoms	Renal Impairment	Neurological symptoms
PET	+	+	±	+++	±	±	++
HELLP	+	++	±	+	+++	+	±
TTP	++	+++	–	±	+	++	+++
HUS	+	++	±	++	+	+++	±
AFLP	±	+	++++	+	+++	++	+
SLE	+	+	±	+	±	++	+
APLS	+	++	±	±	±	±	±

PET, pre-eclampsia; HELLP, haemolysis, elevated liver enzymes and low platelets; TTP, thrombotic thrombocytopenia purpura; HUS, haemolytic-uraemic syndrome; AFLP: acute fatty liver of pregnancy; SLE, systemic lupus erythematosus; APLS, Antiphospholipid syndrome (catastrophic), MAHA, microangiopathic haemolytic anaemia; HBP, hypertension.

#### Drug-associated TTP

Drugs appear to be responsible for <15% of all TTP cases (Vesely *et al*, 2003; Scully *et al*, 2008). Quinine can cause an antibody-mediated idiosyncratic disorder, typically in females. Thienopyridine-associated TTP is well recognized in association with ticlodipine with an incidence of one per 1600–5000 patients treated, but it has rarely been described with clopidogrel and there is uncertainty whether there is a true association (Zakarija *et al*, 2009). Simvastatin (Koduri, 1998; McCarthy *et al*, 1998; Vesely *et al*, 2003; Sundram *et al*, 2004; Scully *et al*, 2008), trimethoprim (Martin *et al*, 2007) and pegylated interferon used to treat hepatitis C (Deutsch *et al*, 2007; Serrano *et al*, 2007; Sallee *et al*, 2008) have been anecdotally associated with antibody-positive TTP.

There are anecdotal reports of acquired TTP associated with oestrogen-containing hormonal preparations such as the combined oral contraceptive pill (COCP) and hormone replacement therapy (Scully *et al*, 2008). Some chemotherapy agents, such as gemcitabine, bleomycin and mitomycin-C can cause HUS but not TTP.

#### Recommendation

- 1 Medications associated with precipitation of TTP include quinine and oestrogen-containing medications, which should be avoided to prevent relapse in patients with a previous episode of TTP (2C).
- 2 Women with previous TTP should be offered non-oestrogen containing contraception (1C).

#### Transplant-associated microangiopathy

Transplant-associated microangiopathy (TAM) is a MAHA and thrombocytopenia that occurs after bone marrow transplantation. It may reflect endothelial toxicity associated with chemotherapy, infections, immunosuppressives, such as ciclosporin A (CSA), and graft-versus-host disease (GVHD). TAM has important differences from *de novo* TTP, namely, absence of ADAMTS13 deficiency; rare neurological symptoms; a

poor response to PEX and lack of evidence of systemic micro-thrombi formation (Ruutu *et al*, 2007).

### *Malignancy-associated thrombotic microangiopathy*

Thrombotic microangiopathy occurs in association with a variety of malignancies, especially adenocarcinomas, (Kwaan & Gordon, 2001). Presentation may be either at an early stage of cancer or associated with disseminated disease. ADAMTS13 activity is not significantly reduced in these patients (Fontana *et al*, 2001).

### *Pancreatitis-associated TTP*

Microangiopathic haemolytic anaemia has recently been reported in association with acute pancreatitis, sometimes a number of days after resolution of pancreatitis. ADAMTS13 activity was only moderately reduced and did not correlate with the severity of TTP or pancreatitis. All patients were successfully treated with PEX and corticosteroids (McDonald *et al*, 2009).

### *Haemolytic uraemic syndrome*

Diarrhoea-positive (D+) HUS, associated typically with verotoxin-induced bloody diarrhoea, is treated with supportive care, which in some cases includes renal dialysis. Diarrhoea negative (D-) HUS, not typically associated with bloody diarrhoea, but may sometimes be associated with multisystem symptoms, similar to TTP, should be urgently treated with PEX (Kim *et al*, 2011). The primary differentiating factor between HUS and TTP is the presence of oliguric/anuric renal impairment/failure in HUS. Increasingly, the role of complement defects in D-, atypical HUS is being defined (Kavanagh & Goodship, 2010) and use of the complement inhibitor, eculizumab, appears successful in these cases (Al-Akash *et al*, 2011; Riedl *et al*, 2011), but may also have a role in severe D+HUS (Lapeyraque *et al*, 2011).

## **Treatment of acute TTP**

A summary of the treatment protocol is shown in Fig 1.

### *Plasma therapy*

Daily PEX, preferably with spun apheresis, is the mainstay of treatment and has reduced mortality rates, from over 90% to 10–20%. It allows removal of autoantibody, and repletes ADAMTS13. Delay in initiation of PEX leads to preventable early mortality (Pereira *et al*, 1995). Although PEX remains the treatment of choice, large volume plasma infusions are indicated if there is to be a delay in arranging PEX. PEX has been shown to be superior to plasma infusion at the end of the first treatment cycle and at 6 months (response rates 47% and 78% vs. 25% and 49%) (Rock *et al*, 1991).

The duration of PEX and the number of procedures required to achieve remission is highly variable, but is longer in antibody-mediated TTP (Coppo *et al*, 2006).

An optimal regimen has not been determined. In the Canadian apheresis trial, 1.5× plasma volume (PV) exchange was performed on the first 3 d followed by 1.0 PV exchange thereafter (Rock *et al*, 1991). More intensive exchange, such as twice daily PEX, may be required in resistant cases especially if there is new symptomatology, such as neurological or cardiac events. The benefit of an intensified PEX regimen has been difficult to document as other treatments are often initiated or intensified simultaneously (Nguyen *et al*, 2008).

Daily exchanges should continue for a minimum of 2 d after complete remission, defined as normal platelet count ( $>150 \times 10^9/l$ ). Tapering (reducing frequency and/or volume of PEX) has not been shown to reduce relapse rates (Bandarenko & Brecher, 1998).

Cryosupernatant is at least as efficacious as standard fresh frozen plasma (FFP) (Rock *et al*, 1996; Brunskill *et al*, 2007). The UK Department of Health recommends the use of solvent/detergent-treated (S/D) plasma (O'Shaughnessy, 2006) in TTP patients to reduce the risk of transfusion-transmitted infection and adverse immune responses (Scully *et al*, 2007b). S/D plasma contains reduced levels of protein S, but an increased thrombotic rate has not been reported in cases where thromboprophylaxis with low molecular weight heparin (LMWH) and low dose aspirin was used routinely once the platelet count was  $>50 \times 10^9/l$  (Scully *et al*, 2007b).

ADAMTS13 activity is present in normal amounts in FFP, S/D plasma, methylene blue-treated FFP (MB-FFP) and psoralen-treated FFP (Yarranton *et al*, 2005).

In the UK, single donor MB-FFP is the recommended plasma for use in all indications in those born after 1st January 1996 to minimize the risk of prion transmission (O'Shaughnessy *et al*, 2004). However MB-FFP has been associated with increased numbers of PEX and longer hospital stay in TTP (de la Rubia *et al*, 2001; Rio-Garma *et al*, 2008). A prospective study using psoralen-FFP compared to standard FFP showed equal efficacy and safety (Mintz *et al*, 2006).

Plasma-related adverse events, such as allergic reactions, anaphylaxis and central venous catheter thrombosis, appeared to be more frequent prior to the use of S/D plasma (Scully *et al*, 2007b).

### *Recommendation*

- 1 PEX should be started with 1.5 PV exchanges, using S/D plasma in all age groups and reassessed daily (1B).**
- 2 The volume of exchange can be reduced to 1.0 PV when the clinical condition and laboratory test results are stabilizing (2C).**
- 3 Intensification in frequency and or volume of PEX procedures should be considered in life-threatening cases (2B).**

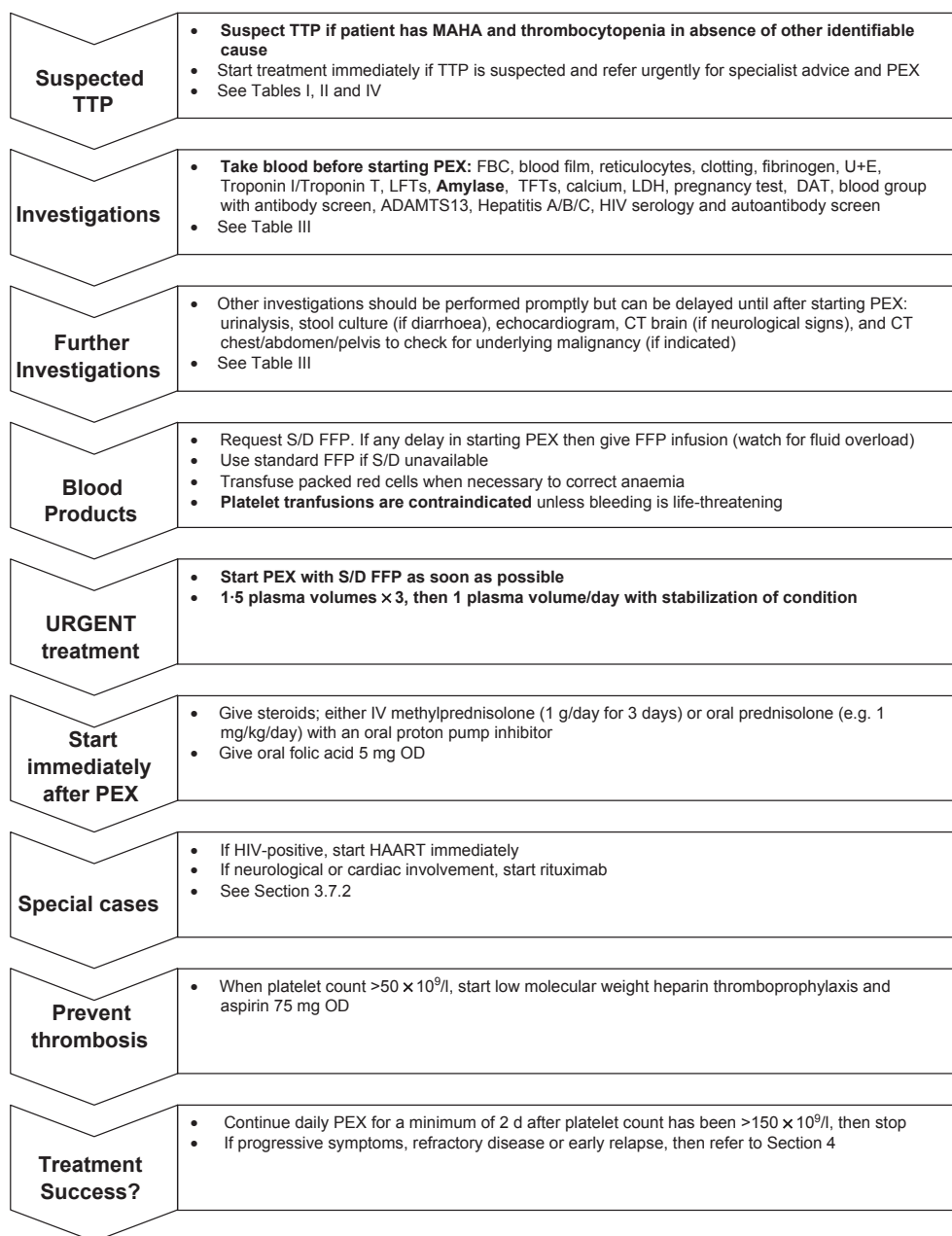


Fig 1. Summary of treatment protocol for acute TTP. TTP, thrombotic thrombocytopenia purpura; MAHA, microangiopathic haemolytic anaemia; PEX, plasma exchange; FBC, full blood count; U + E, urea and electrolytes test; LFTs, liver function tests; LDH, lactate dehydrogenase; DAT, direct antiglobulin test; HIV, human immunodeficiency virus; CT, computerized tomography; S/D FFP, solvent/detergent-treated fresh frozen plasma; IV, intravenously; OD, once daily; HAART, highly active anti retroviral therapy.

**4 Daily PEX should continue for a minimum of 2 d after platelet count has been  $>150 \times 10^9/l$  and then stopped (2B).**

### Congenital TTP

Plasma-derived or recombinant concentrates of ADAMTS13 are not yet available. Therefore current treatment consists of plasma infusion/exchange or the use of a virally-inactivated

intermediate purity factor VIII concentrate containing ADAMTS13, such as 8Y (BPL; BioProducts Laboratory, Elstree, Herts) (Allford *et al*, 2000), which has a small infusion volume and can be given in the outpatient or home setting. 15–30 u/kg of 8Y has been used with reported success, although there is no guaranteed constant quantity of ADAMTS13 in such concentrates. Antibodies to ADAMTS 13 have not been detected following the use of 8Y. Despite that ADAMTS13 has a half-life of only 2–3 d (Furlan *et al*, 1999; Suzuki *et al*,

2004), the clinical effect of infusions of plasma (10–15 ml/kg) or BPL 8Y are such that infusions are required only every 10–20 d, to achieve a normal platelet and haemoglobin level. Ultimately the frequency of treatment depends on the patient's phenotype. Some require regular 'prophylactic' therapy to keep the platelet count normal and avoid relapses at times of infection and other stress situations. The phenotypically mildly affected, who have a normal platelet count most of the time, only require occasional treatment.

### Recommendation

- 1 S/D plasma infusion or intermediate purity Factor VIII (eg BPL 8Y) should be used to treat congenital TTP (1C).**
- 2 Treatment regimens for congenital TTP should be individualized according to the patient's phenotype (1A).**

### Treatment of TTP in pregnancy

Diagnosis of pregnancy-associated TTP is especially difficult if it develops postnatally. In any mother with a TMA, and uncertainty as to the diagnosis (and recognizing that pre-eclampsia and HELLP can present in the postnatal period), PEX should be considered.

If TTP develops in the first trimester, regular PEX may allow continuation of pregnancy with delivery of a live infant (Ambrose *et al*, 1985; Rozdzinski *et al*, 1992; Mokrzycki *et al*, 1995; Scully *et al*, 2006b). Delivery is the definitive treatment of choice for pregnancy-associated TMA, although delivery does not guarantee remission of TTP.

Pre-treatment ADAMTS13 assays will distinguish congenital and acquired TTP from other pregnancy-associated TMAs. In pre-eclampsia and HELLP syndrome ADAMTS13 activity is reduced (median 31% range 12–43%) but antibodies to ADAMTS13 are not found.

Close liaison with an obstetrician with expertise in thrombosis and fetomaternal medicine is required. Serial fetal monitoring with uterine artery dopplers should be used to assess if there is adequate fetal growth and to assess placental blood flow.

Plasma infusions alone may be sufficient in mothers with congenital TTP. However, at delivery PEX may be required to ensure adequate levels of ADAMTS13. The ideal frequency of plasma replacement during pregnancy is unknown.

In acquired TTP, it is difficult to predict future relapse in pregnancy. A reduction in ADAMTS13 activity (<10%) at the start of pregnancy may require elective therapy to prevent microvascular thrombosis during pregnancy. Rituximab has been used in pregnancy in autoimmune disorders and lymphoma (Chakravarty *et al*, 2011).

### Recommendation

- 1 If a TMA cannot be fully explained by a non-TTP pregnancy-related TMA, then the diagnosis of TTP must be considered and PEX should be started (2B).**

- 2 Mothers with congenital TTP should attend a specialist centre and receive ADAMTS13 supplementation regularly throughout pregnancy and the post-partum period (1A).**
- 3 Close liaison with an obstetrician with a special interest in fetomaternal medicine is required in mothers with TTP (1A).**
- 4 In mothers with acquired TTP, ADAMTS13 activity should be monitored throughout pregnancy to help predict the need for adjuvant therapy and outcome (1B).**
- 5 Pre-conceptual counselling is advised for subsequent pregnancies and women of child bearing age should be counselled about potential risks of pregnancy and COCP (2B).**

### HIV-related TTP

In those with severe ADAMTS13 deficiency, there is normalization in ADAMTS13 activity, as the CD4 count recovers and HIV viral load falls, after treatment with HAART and PEX. Occasionally, further therapy is required, for example with rituximab or steroids, which do not cause a significant increase in infectious complications (Hart *et al*, 2011).

Practically, HAART should be given immediately after PEX to allow for maximal time for absorption.

### Recommendation

- 1 If a patient with TTP is found to have HIV infection then viral load should be measured and an HIV physician should be closely involved in management (1A).**
- 2 TTP should be considered in an HIV-positive individual with a MAHA and thrombocytopenia (1A).**
- 3 PEX in conjunction with HAART (triple or quadruple therapy) should be started as soon as the diagnosis of HIV-associated TTP is made (1B).**
- 3 HAART should be given immediately after PEX therapy to maximize time for absorption (1A).**
- 4 HAART should be continued after remission to prevent further relapse (1B).**
- 5 In resistant HIV-related TTP, rituximab could be considered (2B).**

### Bone marrow transplant-associated microangiopathy

Management is difficult, as stopping CSA or switching to another immunosuppressive, such as tacrolimus, may worsen GVHD. No benefit has been shown with PEX; indeed in a retrospective review it was associated with an increased mortality (George *et al*, 2004). There is anecdotal experience of successful use of defibrotide (Bayik *et al*, 1993; Pogliani *et al*, 2000).

### Malignancy-associated thrombotic microangiopathy

Plasma exchange has no benefit (Werner *et al*, 2007). The treatment of the underlying cancer is the mainstay of therapy.

*Recommendation*

- 1 **PEX is not indicated in the management of malignancy and bone marrow transplant-associated TMA (1A).**
- 2 **In cancer associated TMA, further treatment for the underlying cancer should be considered (1A).**

*Further treatments in acquired TTP*

*Corticosteroids.* Steroids are widely used in combination with PEX in the initial treatment of acute immune TTP. Higher dose pulsed steroids have shown to be associated with an improved patient outcome and usually have minimal side effects (Balduini *et al*, 2010). However there is no randomized controlled trial addressing whether a combination of PEX and corticosteroids is superior to PEX alone.

*Recommendation*

**Intravenous daily methylprednisolone (e.g. 1 g/d for three consecutive days – adult dose) or high dose oral prednisolone (e.g. 1 mg/kg/d) should be considered (1B).**

*Rituximab.* Prospective studies have shown that rituximab is effective and safe in immune TTP, when patients failed to respond to daily PEX and methylprednisolone and in relapsed acute idiopathic TTP (Fakhouri *et al*, 2005; Scully *et al*, 2007a). Typically, 375 mg/m<sup>2</sup> has been used weekly for 4 weeks. Patients receiving rituximab showed reductions in anti-ADAMTS13 IgG antibody levels and increased ADAMTS13 activity (Scully *et al*, 2007a). The risk of relapse appears to be reduced with rituximab use (Heidel *et al*, 2007; Scully *et al*, 2011).

Ideally PEX should be withheld for at least 4 h after completing a rituximab infusion (Hull & Eichbaum, 2006; Scully *et al*, 2007a). Giving rituximab more frequently than weekly e.g. every 3–4 d, may overcome removal during PEX (McDonald *et al*, 2010). There is no evidence of increased infection risk with rituximab in TTP patients. A recent Phase II UK study has shown benefit in using rituximab as a first line therapy at presentation of TTP (Scully *et al*, 2011).

*Recommendation*

- 1 **In acute idiopathic TTP with neurological/cardiac pathology, which are associated with a high mortality, rituximab should be considered on admission, in conjunction with PEX and steroids (1B).**
- 2 **Patients with refractory or relapsing immune-mediated TTP should be offered rituximab (1B).**

*Ciclosporin A and tacrolimus.* Ciclosporin A was used successfully in one patient with relapsing TTP (Pasquale *et al*, 1998), but further relapses occurred after cessation of ther-

apy. In a clinical trial of PEX with either steroids or CSA (2–3 mg/kg twice daily), initial remission occurred in 89%, 14% subsequently relapsed while on CSA and there was a 33% relapse after stopping 6 months of CSA treatment.

None of the eight CSA-treated patients suffered a relapse in the first 30 d compared with 6/10 of the steroid-treated patients. Overall 16/18 patients achieved a remission with an increase in ADAMTS13 activity and decrease in antibodies to ADAMTS13 (Cataland *et al*, 2007a,b).

In patients with renal impairment, tacrolimus is an alternative therapy, but side effects may preclude medium and long-term use.

*Recommendation*

**CSA may be considered as second line therapy in patients with acute or chronic relapsing acquired TTP (1C).**

*Other therapies.* With the demonstrated utility and relative safety of rituximab, other drugs previously used for refractory and remitting cases, such as vincristine and cyclophosphamide, whose use is associated with severe side effects, and whose efficacy has been documented in small numbers of patients (Mazzei *et al*, 1998; Bohm *et al*, 2005), are not recommended except as part of a clinical trial.

*Splenectomy.* The mortality of open splenectomy in acute TTP was reported to be approximately 40% (Rutkow, 1978). In a retrospective case series of 33 patients splenectomized for acute refractory and relapsed disease, the 10-year relapse-free survival was 70% (Bohm *et al*, 2005; Kappers-Klunne *et al*, 2005).

*Recommendation*

**Splenectomy may rarely be considered in the non-acute period of immune-mediated TTP but has limited proven benefit (2C).**

*Antiplatelet agents*

The Italian Co-operative Group randomized 72 TTP patients to PEX and steroids with and without aspirin and dipyridole (Bobbio-Pallavicini *et al*, 1997). There was no difference in response rate or excessive haemorrhage and a non-significant decreased rate of early death in the first 15 d in the antiplatelet-treated group (13.5% vs. 2.8%) (Bobbio-Pallavicini *et al*, 1997).

*Recommendation*

- 1 **The clinical efficacy of antiplatelet agents in TTP is unproven but they are relatively safe (1B).**
- 2 **Low dose aspirin (75 mg OD) may be given during platelet recovery (platelet count >50 × 10<sup>9</sup>/l) (2B).**



### Supportive therapy

Red cell transfusion and folic acid supplementation are required during active haemolysis. It has been shown that transfusion in the critically ill is safe using a transfusion trigger of 70 g/l. However this trigger was not applicable to those with cardiac disease (Hebert *et al*, 1999) and, as cardiac microvascular thrombosis is a feature of TTP, a higher haemoglobin level may be required in those with evidence of cardiac involvement and acute haemolysis.

Due to the risk of precipitating further thrombotic events, platelet transfusions are contra-indicated unless there is life-threatening haemorrhage.

The risk of venous thromboembolism has never been formally quantified in acute TTP but is likely to be increased due to immobility and acute illness. Therefore routine LMWH thromboprophylaxis should be given once the platelet count has recovered to  $>50 \times 10^9/l$  (Yarranton *et al*, 2003). Hepatitis B vaccination should be considered in TTP, once a platelet threshold of  $50 \times 10^9/l$  has been achieved, but studies of efficacy are required in the face of continued PEX and/or immunosuppression with rituximab.

### Recommendation

- 1 Red cell transfusion should be administered according to clinical need especially if there is cardiac involvement (1A).
- 2 Folate supplementation is required during active haemolysis (1A).
- 3 Platelet transfusions are contra-indicated in TTP unless there is life-threatening haemorrhage (1A).
- 4 Thromboprophylaxis with LMWH is recommended once platelet count has reached  $>50 \times 10^9/l$  (1B).

### Refractory TTP

There is a subgroup of patients who present with TTP who subsequently show a slow or incomplete response to PEX  $\pm$  corticosteroids. Refractory disease was previously arbitrarily defined as persistent thrombocytopenia or LDH elevation after a total of seven daily PEX procedures. LDH is not however, a reliable marker of disease activity. We have therefore redefined refractory disease as progression of clinical symptoms or persistent thrombocytopenia despite PEX.

Intensification of PEX with the introduction of 12-hourly or double PV exchanges and the addition of further steroids have provided some benefit (Shumak *et al*, 1995; Bobbio-Palavicini *et al*, 1997; Bandarenko & Brecher, 1998; Kahwash & Lockwood, 2004; Nguyen *et al*, 2008). Rituximab is the current agent of choice in refractory disease (Scully *et al*, 2007a).

### Recommendation

**Increased frequency of PEX and addition of rituximab can be considered in refractory TTP (1B).**

### Relapse

Relapse is defined as an episode of acute TTP more than 30 d after remission, and occurs in 20–50% of cases (Shumak *et al*, 1995; Bandarenko & Brecher, 1998; Willis & Bandarenko, 2005). The Canadian Apheresis Group estimated that over a 10-year follow up, 36% of patients would relapse (Shumak *et al*, 1995).

Patients with ADAMTS13 activity  $<10\%$  or an anti-ADAMTS13 antibody in remission had a 3-fold increase in relapse over 1 year (Peyvandi *et al*, 2008). In a further study, if ADAMTS13 was  $<5\%$  in remission, relapse occurred in 38.5%, but if ADAMTS13 activity was  $>15\%$ , only 5% relapsed (Ferrari *et al*, 2007).

The use of rituximab in an acute episode reduces and delays the incidence of relapse (Scully *et al*, 2011). Prior to discharge all patients should be counselled regarding the risk and the symptoms and signs of relapse. In patients who have had previous TTP episodes and where a reduction of ADAMTS 13 activity from detectable levels to  $<5\%$  is demonstrated, elective rituximab therapy has been successfully used, with normalization of ADAMTS 13 activity (Scully *et al*, 2007a; Bresin *et al*, 2009). Patients require long-term follow up with ADAMTS 13 assay monitoring.

### Recommendation

- 1 Increased PEX and/or rituximab therapy are the agents of choice in relapsing disease (1B).
- 2 Patients should be counselled about symptoms, signs and risk of relapse before discharge with verbal and written information (1A).

Table V. Differential Diagnosis of haemolytic uraemic syndrome.

Infection (diarrhoea-positive)	Shiga & verocytotoxin (Shiga-like toxin)-producing bacteria
Disorders of complement regulation (diarrhoea-negative)	Genetic disorders of complement regulation e.g. Factor H, I, MCP (CD46), factor B (CFB), C3 (C3), thrombomodulin Acquired disorders of complement regulation e.g. anti-FH antibody
Other causes of secondary HUS	<i>Streptococcus pneumoniae</i> HIV Malignancy Defective cobalamin metabolism Drugs e.g. quinine, some chemotherapy e.g. gemcitabine, bleomycin Pregnancy Other autoimmune diseases e.g. SLE, APLS

HUS, haemolytic uraemic syndrome; HIV, human immunodeficiency virus; SLE, systemic lupus erythematosus; APLS, antiphospholipid syndrome.

**3 In patients with a documented reduction of ADAMTS 13 activity to <5%, elective therapy with rituximab can be considered (1B).**

### Haemolytic uraemic syndrome

Haemolytic uraemic syndrome is characterized by MAHA, thrombocytopenia and acute renal failure. It may be associated with extensive multi-organ involvement, e.g. neurological, hepatic complications, and cardiac problems and therefore diagnostic overlap with TTP can occur. It is important to differentiate between D + HUS, atypical HUS and TTP because the prognosis and management are different (Table V). The reader is referred to (Ariceta *et al*, 2009) and (Taylor *et al*, 2010) for further guidance in children and adults, respectively.

### Conclusion

TTP and other TMAs remain diagnostically difficult. The current challenge is to ensure that haematologists, physicians, obstetricians and paediatricians are aware of the need to treat acute TTP as a medical emergency to prevent unnecessary early mortality. The development of new drugs and recombinant proteins, trialled in the developing networks should lead to better treatments in the future.

### Disclaimer

While the advice and information in these guidelines is believed to be true and accurate at the time of going to

press, neither the authors, the British Society for Haematology nor the publishers accept any legal responsibility for the content of these guidelines.

### Guideline update

In 2003, the British Society for Haematology (BCSH) published the first evidence-based guidelines for the diagnosis and management of thrombotic microangiopathies (Allford *et al*, 2003). We have revised these based on new evidence available between 2003 and 2011.

Separate guidelines for atypical haemolytic-uraemic syndrome (HUS) (Taylor *et al*, 2010) and diarrhoea-positive HUS (Ariceta *et al*, 2009) are now available, so these sections have been reduced.

### Acknowledgements

Dr Michael J Desborough, Academic Clinical Fellow, Oxford Deanery UK for review of Fig 1 and Ms Lucy MacKillop, Obstetric Physician, Oxford Universities Hospital Trust for review of Table IV.

### Conflicts of interest

The Haemostasis Research unit, UCL has received an unrestricted educational grant from Octapharma, UK.

### References

- Al-Akash, S.I., Almond, P.S., Savell, Jr, V.H., Ghayraybeh, S.I. & Hogue, C. (2011) Eculizumab induces long-term remission in recurrent post-transplant HUS associated with C3 gene mutation. *Pediatric Nephrology (Berlin, Germany)*, **26**, 613–619.
- Allford, S.L., Harrison, P., Lawrie, A.S., Liesner, R., MacKie, I.J. & Machin, S.J. (2000) Von Willebrand factor–cleaving protease activity in congenital thrombotic thrombocytopenic purpura. *British Journal of Haematology*, **111**, 1215–1222.
- Allford, S.L., Hunt, B.J., Rose, P. & Machin, S.J. (2003) Guidelines on the diagnosis and management of the thrombotic microangiopathic haemolytic anaemias. *British Journal of Haematology*, **120**, 556–573.
- Ambrose, A., Welham, R.T. & Cefalo, R.C. (1985) Thrombotic thrombocytopenic purpura in early pregnancy. *Obstetrics and Gynecology*, **66**, 267–272.
- Ariceta, G., Besbas, N., Johnson, S., Karpman, D., Landau, D., Licht, C., Loirat, C., Pecoraro, C., Taylor, C.M., Van de Kar, N., Vandewalle, J. & Zimmerhackl, L.B. (2009) Guideline for the investigation and initial therapy of diarrhea-negative hemolytic uremic syndrome. *Pediatric Nephrology (Berlin, Germany)*, **24**, 687–696.
- Balduini, C.L., Gugliotta, L., Luppi, M., Laurenti, L., Klersy, C., Pieresca, C., Quintini, G., Iuliano, F., Re, R., Spedini, P., Vianelli, N., Zaccaria, A., Pogliani, E.M., Musso, R., Bobbio, P.E., Quarta, G., Galieni, P., Fragasso, A., Casella, G., Noris, P. & Ascari, E. (2010) High versus standard dose methylprednisolone in the acute phase of idiopathic thrombotic thrombocytopenic purpura: a randomized study. *Annals of Hematology*, **89**, 591–596.
- Bandarenko, N. & Brecher, M.E. (1998) United States Thrombotic Thrombocytopenic Purpura Apheresis Study Group (US TTP ASG): multicenter survey and retrospective analysis of current efficacy of therapeutic plasma exchange. *Journal of Clinical Apheresis*, **13**, 133–141.
- Bayik, M.M., Akoglu, T., Tuğlular, T.F., Akoglu, E., Tezal, M., Ulutin, O. & Lawrence, R. (1993) Treatment of thrombotic thrombocytopenic purpura with defibrotid. *American Journal of Hematology*, **43**, 74–75.
- Bianchi, V., Robles, R., Alberio, L., Furlan, M. & Lammler, B. (2002) Von Willebrand factor–cleaving protease (ADAMTS13) in thrombocytopenic disorders: a severely deficient activity is specific for thrombotic thrombocytopenic purpura. *Blood*, **100**, 710–713.
- Bobbio-Pallavicini, E., Gugliotta, L., Centurioni, R., Porta, C., Vianelli, N., Billio, A., Tacconi, F. & Ascari, E. (1997) Antiplatelet agents in thrombotic thrombocytopenic purpura (TTP). Results of a randomized multicenter trial by the Italian Cooperative Group for TTP. *Haematologica*, **82**, 429–435.
- Bohm, M., Betz, C., Miesbach, W., Krause, M., von Auer, C., Geiger, H. & Scharrer, I. (2005) The course of ADAMTS-13 activity and inhibitor titre in the treatment of thrombotic thrombocytopenic purpura with plasma exchange and vincristine. *British Journal of Haematology*, **129**, 644–652.
- Bresin, E., Gastoldi, S., Daina, E., Belotti, D., Pogliani, E., Perseghin, P., Scalzulli, P.R., Paolini, R., Marceno, R., Remuzzi, G. & Galbusera, M. (2009) Rituximab as pre-emptive treatment in patients with thrombotic thrombocytopenic purpura and evidence of anti-ADAMTS13 autoantibodies. *Thrombosis and Haemostasis*, **101**, 233–238.
- Brunskill, S.J., Tusold, A., Benjamin, S., Stanworth, S.J. & Murphy, M.F. (2007) A systematic review of randomized controlled trials for plasma

- exchange in the treatment of thrombotic thrombocytopenic purpura. *Transfusion Medicine (Oxford, England)*, **17**, 17–25.
- Cataland, S.R., Jin, M., Ferketich, A.K., Kennedy, M.S., Kraut, E.H., George, J.N. & Wu, H.M. (2007a) An evaluation of cyclosporin and corticosteroids individually as adjuncts to plasma exchange in the treatment of thrombotic thrombocytopenic purpura. *British Journal of Haematology*, **136**, 146–149.
- Cataland, S.R., Jin, M., Lin, S., Kennedy, M.S., Kraut, E.H., George, J.N. & Wu, H.M. (2007b) Cyclosporin and plasma exchange in thrombotic thrombocytopenic purpura: long-term follow-up with serial analysis of ADAMTS13 activity. *British Journal of Haematology*, **139**, 486–493.
- Chakravarty, E.F., Murray, E.R., Kelman, A. & Farmer, P. (2011) Pregnancy outcomes after maternal exposure to rituximab. *Blood*, **117**, 1499–1506.
- Coppo, P., Wolf, M., Veyradier, A., Bussel, A., Malot, S., Millot, G.A., Daubin, C., Bordessoule, D., Pene, F., Mira, J.P., Heshmati, F., Maury, E., Guidet, B., Boulanger, E., Galicier, L., Parquet, N., Vernant, J.P., Rondeau, E., Azoulay, E. & Schlemmer, B. (2006) Prognostic value of inhibitory anti-ADAMTS13 antibodies in adult-acquired thrombotic thrombocytopenic purpura. *British Journal of Haematology*, **132**, 66–74.
- Dervenoulas, J., Tsigotis, P., Bollas, G., Pappa, V., Xiros, N., Economopoulos, T., Pappa, M., Mellou, S., Kostourou, A., Papageorgiou, E. & Raptis, S.A. (2000) Thrombotic thrombocytopenic purpura/hemolytic uremic syndrome (TTP/HUS): treatment outcome, relapses, prognostic factors. A single-center experience of 48 cases. *Annals of Hematology*, **79**, 66–72.
- Deutsch, M., Manesis, E.K., Hadziyannis, E., Vassilopoulos, D. & Archimandritis, A.J. (2007) Thrombotic thrombocytopenic purpura with fatal outcome in a patient with chronic hepatitis C treated with pegylated interferon- $\alpha$ /2b. *Scandinavian Journal of Gastroenterology*, **42**, 408–409.
- Dudloy-Bouthors, A.S., Caron, C., Subtil, D., Provot, F., Tournoy, A., Wibau, B. & Krivosic-Horber, R. (2003) Thrombotic thrombocytopenic purpura: medical and biological monitoring of six pregnancies. *European Journal of Obstetrics, Gynecology, and Reproductive Biology*, **111**, 146–152.
- Fakhouri, F., Vernant, J.P., Veyradier, A., Wolf, M., Kaplanski, G., Binaut, R., Rieger, M., Scheiflinger, F., Poullin, P., Derouere, B., Delarue, R., Lesavre, P., Vanhille, P., Hermine, O., Remuzzi, G. & Grunfeld, J.P. (2005) Efficiency of curative and prophylactic treatment with rituximab in ADAMTS13-deficient thrombotic thrombocytopenic purpura: a study of 11 cases. *Blood*, **106**, 1932–1937.
- Ferrari, S., Scheiflinger, F., Rieger, M., Mudde, G., Wolf, M., Coppo, P., Girma, J.P., Azoulay, E., Brun-Buisson, C., Fakhouri, F., Mira, J.P., Oksenhendler, E., Poullin, P., Rondeau, E., Schleinitz, N., Schlemmer, B., Teboul, J.L., Vanhille, P., Vernant, J.P., Meyer, D. & Veyradier, A. (2007) Prognostic value of anti-ADAMTS 13 antibody features (Ig isotype, titer, and inhibitory effect) in a cohort of 35 adult French patients undergoing a first episode of thrombotic microangiopathy with undetectable ADAMTS 13 activity. *Blood*, **109**, 2815–2822.
- Fontana, S., Gerritsen, H.E., Kremer, H.J., Furlan, M. & Lammle, B. (2001) Microangiopathic hemolytic anaemia in metastasizing malignant tumours is not associated with a severe deficiency of the von Willebrand factor-cleaving protease. *British Journal of Haematology*, **113**, 100–102.
- Fujikawa, K., Suzuki, H., McMullen, B. & Chung, D. (2001) Purification of human von Willebrand factor-cleaving protease and its identification as a new member of the metalloproteinase family. *Blood*, **98**, 1662–1666.
- Fujimura, Y., Matsumoto, M., Kokame, K., Isonishi, A., Soejima, K., Akiyama, N., Tomiyama, J., Natori, K., Kuranishi, Y., Imamura, Y., Inoue, N., Higasa, S., Seike, M., Kozuka, T., Hara, M., Wada, H., Murata, M., Ikeda, Y., Miyata, T. & George, J.N. (2009) Pregnancy-induced thrombocytopenia and TTP, and the risk of fetal death, in Upshaw-Schulman syndrome: a series of 15 pregnancies in 9 genotyped patients. *British Journal of Haematology*, **144**, 742–754.
- Fujimura, Y., Matsumoto, M., Isonishi, A., Yagi, H., Kokame, K., Soejima, K., Murata, M. & Miyata, T. (2011) Natural history of Upshaw-Schulman syndrome based on ADAMTS13 gene analysis in Japan. *Journal of Thrombosis and Haemostasis*, **9**(Suppl 1), 283–301.
- Furlan, M., Robles, R., Solenthaler, M., Wassmer, M., Sandoz, P. & Lammle, B. (1997) Deficient activity of von Willebrand factor-cleaving protease in chronic relapsing thrombotic thrombocytopenic purpura. *Blood*, **89**, 3097–3103.
- Furlan, M., Robles, R., Solenthaler, M. & Lammle, B. (1998a) Acquired deficiency of von Willebrand factor-cleaving protease in a patient with thrombotic thrombocytopenic purpura. *Blood*, **91**, 2839–2846.
- Furlan, M., Robles, R., Galbusera, M., Remuzzi, G., Kyrle, P.A., Brenner, B., Krause, M., Scharer, I., Aumann, V., Mittler, U., Solenthaler, M. & Lammle, B. (1998b) von Willebrand factor-cleaving protease in thrombotic thrombocytopenic purpura and the hemolytic-uremic syndrome. *New England Journal of Medicine*, **339**, 1578–1584.
- Furlan, M., Robles, R., Morselli, B., Sandoz, P. & Lammle, B. (1999) Recovery and half-life of von Willebrand factor-cleaving protease after plasma therapy in patients with thrombotic thrombocytopenic purpura. *Thrombosis and Haemostasis*, **81**, 8–13.
- Galbusera, M., Noris, M. & Remuzzi, G. (2006) Thrombotic thrombocytopenic purpura—then and now. *Seminars in Thrombosis and Hemostasis*, **32**, 81–89.
- Gami, A.S., Hayman, S.R., Grande, J.P. & Garovic, V.D. (2005) Incidence and prognosis of acute heart failure in the thrombotic microangiopathies. *American Journal of Medicine*, **118**, 544–547.
- George, J.N., Li, X., McMinn, J.R., Terrell, D.R., Vesely, S.K. & Selby, G.B. (2004) Thrombotic thrombocytopenic purpura-hemolytic uremic syndrome following allogeneic HPC transplantation: a diagnostic dilemma. *Transfusion*, **44**, 294–304.
- Gervasoni, C., Ridolfo, A.L., Vaccarezza, M., Parravicini, C., Vago, L., Adorni, F., Cappelletti, A., d'Arminio, M.A. & Galli, M. (2002) Thrombotic microangiopathy in patients with acquired immunodeficiency syndrome before and during the era of introduction of highly active antiretroviral therapy. *Clinical Infectious Diseases*, **35**, 1534–1540.
- Hart, D., Sayer, R., Miller, R., Edwards, S., Kelly, A., Baglin, T., Hunt, B., Benjamin, S., Patel, R., Machin, S. & Scully, M. (2011) Human immunodeficiency virus associated thrombotic thrombocytopenic purpura-favourable outcome with plasma exchange and prompt initiation of highly active antiretroviral therapy. *British Journal of Haematology*, **153**, 515–519.
- Hebert, P.C., Wells, G., Blajchman, M.A., Marshall, J., Martin, C., Pagliarello, G., Tweeddale, M., Schweitzer, I. & Yetisir, E. (1999) A multicenter, randomized, controlled clinical trial of transfusion requirements in critical care. Transfusion Requirements in Critical Care Investigators, Canadian Critical Care Trials Group. *New England Journal of Medicine*, **340**, 409–417.
- Heidel, F., Lipka, D.B., von Auer, C., Huber, C., Scharer, I. & Hess, G. (2007) Addition of rituximab to standard therapy improves response rate and progression-free survival in relapsed or refractory thrombotic thrombocytopenic purpura and autoimmune haemolytic anaemia. *Thrombosis and Haemostasis*, **97**, 228–233.
- Hughes, C., McEwan, J.R., Longair, I., Hughes, S., Cohen, H., Machin, S. & Scully, M. (2009) Cardiac involvement in acute thrombotic thrombocytopenic purpura: association with troponin T and IgG antibodies to ADAMTS 13. *Journal of Thrombosis and Haemostasis*, **7**, 529–536.
- Hull, M.J. & Eichbaum, Q.G. (2006) Efficacy of rituximab and concurrent plasma exchange in the treatment of thrombotic thrombocytopenic purpura. *Clinical Advances in Hematology & Oncology*, **4**, 210–214.
- Kahwash, E. & Lockwood, W.B. (2004) Twice daily plasma exchange in refractory thrombotic thrombocytopenic purpura. *Therapeutic Apheresis and Dialysis*, **8**, 254–257.
- Kappers-Klunne, M.C., Wijermans, P., Fijnheer, R., Croockewit, A.J., van der, H.B., de Wolf, J. T., Lowenberg, B. & Brand, A. (2005) Splenectomy for the treatment of thrombotic thrombocytopenic purpura. *British Journal of Haematology*, **130**, 768–776.
- Kavanagh, D. & Goodship, T.H. (2010) Atypical hemolytic uremic syndrome. *Current Opinion in Hematology*, **17**, 432–438.
- Kim, J.J., Goodship, T.H., Tizard, J. & Inward, C. (2011) Plasma therapy for atypical haemolytic

- uraemic syndrome associated with heterozygous factor H mutations. *Pediatric Nephrology (Berlin, Germany)*, **26**, 2073–2076.
- Koduri, P.R. (1998) Simvastatin and thrombotic thrombocytopenic purpura. *Lancet*, **352**, 2020.
- Kwaan, H.C. & Gordon, L.I. (2001) Thrombotic microangiopathy in the cancer patient. *Acta Haematologica*, **106**, 52–56.
- de la Rubia, J., Arriaga, F., Linares, D., Larrea, L., Carpio, N., Marty, M.L. & Sanz, M.A. (2001) Role of methylene blue-treated or fresh-frozen plasma in the response to plasma exchange in patients with thrombotic thrombocytopenic purpura. *British Journal of Haematology*, **114**, 721–723.
- Lapeyraque, A.L., Malina, M., Fremeaux-Bacchi, V., Boppel, T., Kirschfink, M., Oualha, M., Prox, F., Clermont, M.J., Le, D.F., Niaudet, P. & Schaefer, F. (2011) Eculizumab in severe Shiga-toxin-associated HUS. *New England Journal of Medicine*, **364**, 2561–2563.
- Levy, G.G., Nichols, W.C., Lian, E.C., Foroud, T., McClintick, J.N., McGee, B.M., Yang, A.Y., Siemieniak, D.R., Stark, K.R., Gruppo, R., Sarode, R., Shurin, S.B., Chandrasekaran, V., Stabler, S. P., Sabio, H., Bouhassira, E.E., Upshaw, Jr, J.D., Ginsburg, D. & Tsai, H.M. (2001) Mutations in a member of the ADAMTS gene family cause thrombotic thrombocytopenic purpura. *Nature*, **413**, 488–494.
- Loirat, C., Veyradier, A., Girma, J.P., Ribba, A.S. & Meyer, D. (2006) Thrombotic thrombocytopenic purpura associated with von Willebrand factor-cleaving protease (ADAMTS13) deficiency in children. *Seminars in Thrombosis and Hemostasis*, **32**, 90–97.
- Loof, A.H., van Vliet, H.H. & Kappers-Klunne, M. C. (2001) Low activity of von Willebrand factor-cleaving protease is not restricted to patients suffering from thrombotic thrombocytopenic purpura. *British Journal of Haematology*, **112**, 1087–1088.
- Malak, S., Wolf, M., Millot, G.A., Mariotte, E., Veyradier, A., Meynard, J.L., Korach, J.M., Malot, S., Bussel, A., Azoulay, E., Boulanger, E., Galicier, L., Devaux, E., Eschwege, V., Gallien, S., Adrie, C., Schlemmer, B., Rondeau, E. & Coppo, P. (2008) Human immunodeficiency virus-associated thrombotic microangiopathies: clinical characteristics and outcome according to ADAMTS13 activity. *Scandinavian Journal of Immunology*, **68**, 337–344.
- Mannucci, P.M., Canciani, M.T., Forza, I., Lussana, F., Lattuada, A. & Rossi, E. (2001) Changes in health and disease of the metalloprotease that cleaves von Willebrand factor. *Blood*, **98**, 2730–2735.
- Martin, M.G., Whitlatch, N.L., Shah, B. & Arepally, G.M. (2007) Thrombotic thrombocytopenic purpura induced by trimethoprim-sulfamethoxazole in a Jehovah's Witness. *American Journal of Hematology*, **82**, 679–681.
- Mazzei, C., Pepkowitz, S., Klapper, E. & Goldfinger, D. (1998) Treatment of thrombotic thrombocytopenic purpura: a role for early vincristine administration. *Journal of Clinical Apheresis*, **13**, 20–22.
- McCarthy, L.J., Porcu, P., Fausel, C.A., Sweeney, C.J. & Danielson, C.F. (1998) Thrombotic thrombocytopenic purpura and simvastatin. *Lancet*, **352**, 1284–1285.
- McDonald, V., Laffan, M., Benjamin, S., Bevan, D., Machin, S. & Scully, M.A. (2009) Thrombotic thrombocytopenic purpura precipitated by acute pancreatitis: a report of seven cases from a regional UK TTP registry. *British Journal of Haematology*, **144**, 430–433.
- McDonald, V., Manns, K., MacKie, I.J., Machin, S. J. & Scully, M.A. (2010) Rituximab pharmacokinetics during the management of acute idiopathic thrombotic thrombocytopenic purpura. *Journal of Thrombosis and Haemostasis*, **8**, 1201–1208.
- Miller, D.P., Kaye, J.A., Shea, K., Ziyadeh, N., Cali, C., Black, C. & Walker, A.M. (2004) Incidence of thrombotic thrombocytopenic purpura/hemolytic uremic syndrome. *Epidemiology*, **15**, 208–215.
- Miller, R.F., Scully, M., Cohen, H., Roedling, S., Starke, R., Edwards, S.G. & Machin, S.J. (2005) Thrombotic thrombocytopenic purpura in HIV-infected patients. *International Journal of STD and AIDS*, **16**, 538–542.
- Mintz, P.D., Neff, A., Mackenzie, M., Goodnough, L.T., Hillyer, C., Kessler, C., McCrae, K., Menitove, J.E., Skikne, B.S., Damon, L., Lopez-Plaza, I., Rouault, C., Crookston, K.P., Benjamin, R.J., George, J., Lin, J.S., Corash, L. & Conlan, M.G. (2006) A randomized, controlled Phase III trial of therapeutic plasma exchange with fresh-frozen plasma (FFP) prepared with amotosalen and ultraviolet A light compared to untreated FFP in thrombotic thrombocytopenic purpura. *Transfusion*, **46**, 1693–1704.
- Mokrzycki, M.H., Rickles, F.R., Kaplan, A.A. & Kohn, O.F. (1995) Thrombotic thrombocytopenic purpura in pregnancy: successful treatment with plasma exchange. Case report and review of the literature. *Blood Purification*, **13**, 271–282.
- Moore, J.C., Hayward, C.P., Warkentin, T.E. & Kelton, J.G. (2001) Decreased von Willebrand factor protease activity associated with thrombotic thrombocytopenic purpura. *Blood*, **98**, 1842–1846.
- Nguyen, L., Li, X., Duvall, D., Terrell, D.R., Vesely, S.K. & George, J.N. (2008) Twice-daily plasma exchange for patients with refractory thrombotic thrombocytopenic purpura: the experience of the Oklahoma Registry, 1989 through 2006. *Transfusion*, **48**, 349–357.
- O'Shaughnessy, D. (2006) Availability of imported fresh frozen plasma in England and North Wales. Department of Health Gateway reference 5999. URL: [http://www.dh.gov.uk/prod\\_consum\\_dh/groups/dh\\_digitalassets/@dh/@en/documents/digitalasset/dh\\_4127680.pdf](http://www.dh.gov.uk/prod_consum_dh/groups/dh_digitalassets/@dh/@en/documents/digitalasset/dh_4127680.pdf)
- O'Shaughnessy, D.F., Atterbury, C., Bolton, M.P., Murphy, M., Thomas, D., Yates, S. & Williamson, L.M. (2004) Guidelines for the use of fresh-frozen plasma, cryoprecipitate and cryosupernatant. *British Journal of Haematology*, **126**, 11–28.
- Pasquale, D., Vidhya, R., DaSilva, K., Tsan, M.F., Lansing, L. & Chikkappa, G. (1998) Chronic relapsing thrombotic thrombocytopenic purpura: role of therapy with cyclosporine. *American Journal of Hematology*, **57**, 57–61.
- Pereira, A., Mazzara, R., Monteagudo, J., Sanz, C., Puig, L., Martinez, A., Ordinas, A. & Castillo, R. (1995) Thrombotic thrombocytopenic purpura/hemolytic uremic syndrome: a multivariate analysis of factors predicting the response to plasma exchange. *Annals of Hematology*, **70**, 319–323.
- Peyvandi, F., Ferrari, S., Lavoretano, S., Canciani, M.T. & Mannucci, P.M. (2004) von Willebrand factor cleaving protease (ADAMTS-13) and ADAMTS-13 neutralizing autoantibodies in 100 patients with thrombotic thrombocytopenic purpura. *British Journal of Haematology*, **127**, 433–439.
- Peyvandi, F., Lavoretano, S., Palla, R., Feys, H.B., Vanhoorelbeke, K., Battaglioli, T., Valsecchi, C., Canciani, M.T., Fabris, F., Zver, S., Reti, M., Mikovic, D., Karimi, M., Giuffrida, G., Laurenti, L. & Mannucci, P.M. (2008) ADAMTS13 and anti-ADAMTS13 antibodies as markers for recurrence of acquired thrombotic thrombocytopenic purpura during remission. *Haematologica*, **93**, 232–239.
- Peyvandi, F., Palla, R., Lotta, L.A., Mackie, I., Scully, M.A. & Machin, S.J. (2010) ADAMTS-13 assays in thrombotic thrombocytopenic purpura. *Journal of Thrombosis and Haemostasis*, **8**, 631–640.
- Pogliani, E.M., Perseghin, P., Parma, M., Pioltelli, P. & Corneo, G. (2000) Defibrinogen in recurrent thrombotic thrombocytopenic purpura. *Clinical and Applied Thrombosis/Hemostasis*, **6**, 69–70.
- Ridolfi, R.L. & Bell, W.R. (1981) Thrombotic thrombocytopenic purpura. Report of 25 cases and review of the literature. *Medicine (Baltimore)*, **60**, 413–428.
- Riedl, M., Rosales, A., Zimmerhackl, L.B. & Junggraithmayr, T. (2011) Actual and future strategies for transplantation in atypical HUS associated with mutations in factor H. *Pediatric Transplantation*, **15**, 225–228.
- Rio-Garma, J., Alvarez-Larran, A., Martinez, C., Muncunill, J., Castella, D., de la, R.J., Zamora, C., Corral, M., Viejo, A., Pena, F., Rodriguez-Vicente, P., Contreras, E., Arbona, C., Ramirez, C., Garcia-Erce, J.A., Alegre, A., Mateo, J. & Pereira, A. (2008) Methylene blue-photoactivated plasma versus quarantine fresh frozen plasma in thrombotic thrombocytopenic purpura: a multicentric, prospective cohort study. *British Journal of Haematology*, **143**, 39–45.
- Rock, G.A., Shumak, K.H., Buskard, N.A., Blanchette, V.S., Kelton, J.G., Nair, R.C. & Spasoff, R. A. (1991) Comparison of plasma exchange with plasma infusion in the treatment of thrombotic thrombocytopenic purpura. Canadian Apheresis Study Group. *New England Journal of Medicine*, **325**, 393–397.
- Rock, G., Shumak, K.H., Sutton, D.M., Buskard, N.A. & Nair, R.C. (1996) Cryosupernatant as replacement fluid for plasma exchange in

- thrombotic thrombocytopenic purpura. Members of the Canadian Apheresis Group. *British Journal of Haematology*, **94**, 383–386.
- Rozdzinski, E., Hertenstein, B., Schmeiser, T., Seifried, E., Kurrle, E. & Heimpel, H. (1992) Thrombotic thrombocytopenic purpura in early pregnancy with maternal and fetal survival. *Annals of Hematology*, **64**, 245–248.
- Rutkow, I.M. (1978) Thrombotic thrombocytopenic purpura (TTP) and splenectomy: a current appraisal. *Annals of Surgery*, **188**, 701–705.
- Ruutu, T., Barosi, G., Benjamin, R.J., Clark, R.E., George, J.N., Gratwohl, A., Holler, E., Iacobelli, M., Kentouche, K., Lammle, B., Moake, J.L., Richardson, P., Socie, G., Zeigler, Z., Niederwieser, D. & Barbui, T. (2007) Diagnostic criteria for hematopoietic stem cell transplant-associated microangiopathy: results of a consensus process by an International Working Group. *Haematologica*, **92**, 95–100.
- Sallee, M., Cretel, E., Jean, R., Chiche, L., Bourliere, M., Poullin, P., Lefevre, P. & Durand, J.M. (2008) Thrombotic thrombocytopenic purpura complicating interferon therapy in chronic C hepatitis. *Gastroenterologie Clinique et Biologique*, **32**, 145–146.
- Schiff, D.E., Roberts, W.D., Willert, J. & Tsai, H.M. (2004) Thrombocytopenia and severe hyperbilirubinemia in the neonatal period secondary to congenital thrombotic thrombocytopenic purpura and ADAMTS13 deficiency. *Journal of Pediatric Hematology/Oncology*, **26**, 535–538.
- Schneppenheim, R., Budde, U., Oyen, F., Angerhaus, D., Aumann, V., Drewke, E., Hassenpflug, W., Haberle, J., Kentouche, K., Kohne, E., Kurnik, K., Mueller-Wiefel, D., Obser, T., Santer, R. & Sykora, K.W. (2003) von Willebrand factor cleaving protease and ADAMTS13 mutations in childhood TTP. *Blood*, **101**, 1845–1850.
- Scully, M., Gattens, M., Khair, K. & Liesner, R. (2006a) The use of intermediate purity factor VIII concentrate BPL 8Y as prophylaxis and treatment in congenital thrombotic thrombocytopenic purpura. *British Journal of Haematology*, **135**, 101–104.
- Scully, M., Starke, R., Lee, R., Mackie, I., Machin, S. & Cohen, H. (2006b) Successful management of pregnancy in women with a history of thrombotic thrombocytopenic purpura. *Blood Coagulation & Fibrinolysis*, **17**, 459–463.
- Scully, M., Cohen, H., Cavenagh, J., Benjamin, S., Starke, R., Killick, S., Mackie, I. & Machin, S.J. (2007a) Remission in acute refractory and relapsing thrombotic thrombocytopenic purpura following rituximab is associated with a reduction in IgG antibodies to ADAMTS-13. *British Journal of Haematology*, **136**, 451–461.
- Scully, M., Longair, I., Flynn, M., Berryman, J. & Machin, S.J. (2007b) Cryosupernatant and solvent detergent fresh-frozen plasma (Octaplas) usage at a single centre in acute thrombotic thrombocytopenic purpura. *Vox Sanguinis*, **93**, 154–158.
- Scully, M., Yarranton, H., Liesner, R., Cavenagh, J., Hunt, B., Benjamin, S., Bevan, D., Mackie, I. & Machin, S. (2008) Regional UK TTP registry: correlation with laboratory ADAMTS 13 analysis and clinical features. *British Journal of Haematology*, **142**, 819–826.
- Scully, M., McDonald, V., Cavenagh, J., Hunt, B.J., Longair, I., Cohen, H. & Machin, S.J. (2011) A phase 2 study of the safety and efficacy of rituximab with plasma exchange in acute acquired thrombotic thrombocytopenic purpura. *Blood*, **118**, 1746–1753.
- Serrano, A., Xicoy, B., Grifols, J.R. & Ribera, J.M. (2007) [Thrombotic thrombocytopenic purpura during treatment with interferon]. *Medicina clinica (Barcelona)*, **128**, 276–277.
- Shumak, K.H., Rock, G.A. & Nair, R.C. (1995) Late relapses in patients successfully treated for thrombotic thrombocytopenic purpura. Canadian Apheresis Group. *Annals of Internal Medicine*, **122**, 569–572.
- Sundram, F., Roberts, P., Kennedy, B. & Pavord, S. (2004) Thrombotic thrombocytopenic purpura associated with statin treatment. *Postgraduate Medical Journal*, **80**, 551–552.
- Suzuki, M., Murata, M., Matsubara, Y., Uchida, T., Ishihara, H., Shibano, T., Ashida, S., Soejima, K., Okada, Y. & Ikeda, Y. (2004) Detection of von Willebrand factor-cleaving protease (ADAMTS-13) in human platelets. *Biochemical and Biophysical Research Communications*, **313**, 212–216.
- Taylor, C.M., Machin, S., Wigmore, S.J. & Goodship, T.H. (2010) Clinical practice guidelines for the management of atypical haemolytic uraemic syndrome in the United Kingdom. *British Journal of Haematology*, **148**, 37–47.
- Terrell, D.R., Williams, L.A., Vesely, S.K., Lammle, B., Hovinga, J.A. & George, J.N. (2005) The incidence of thrombotic thrombocytopenic purpura-hemolytic uremic syndrome: all patients, idiopathic patients, and patients with severe ADAMTS-13 deficiency. *Journal of Thrombosis and Haemostasis*, **3**, 1432–1436.
- Tsai, H.M. & Lian, E.C. (1998) Antibodies to von Willebrand factor-cleaving protease in acute thrombotic thrombocytopenic purpura. *New England Journal of Medicine*, **339**, 1585–1594.
- Tuncer, H.H., Oster, R.A., Huang, S.T. & Marques, M.B. (2007) Predictors of response and relapse in a cohort of adults with thrombotic thrombocytopenic purpura-hemolytic uremic syndrome: a single-institution experience. *Transfusion*, **47**, 107–114.
- Ucar, A., Fernandez, H.F., Byrnes, J.J., Lian, E.C. & Harrington, Jr, W.J. (1994) Thrombotic microangiopathy and retroviral infections: a 13-year experience. *American Journal of Hematology*, **45**, 304–309.
- Vesely, S.K., George, J.N., Lammle, B., Studt, J.D., Alberio, L., El Harake, M.A. & Raskob, G.E. (2003) ADAMTS13 activity in thrombotic thrombocytopenic purpura-hemolytic uremic syndrome: relation to presenting features and clinical outcomes in a prospective cohort of 142 patients. *Blood*, **102**, 60–68.
- Vesely, S.K., Li, X., McMinn, J.R., Terrell, D.R. & George, J.N. (2004) Pregnancy outcomes after recovery from thrombotic thrombocytopenic purpura-hemolytic uremic syndrome. *Transfusion*, **44**, 1149–1158.
- Veyradier, A., Obert, B., Haddad, E., Cloarec, S., Nivet, H., Foulard, M., Lesure, F., Delattre, P., Lakhdari, M., Meyer, D., Girma, J.P. & Loirat, C. (2003) Severe deficiency of the specific von Willebrand factor-cleaving protease (ADAMTS 13) activity in a subgroup of children with atypical hemolytic uremic syndrome. *Journal of Pediatrics*, **142**, 310–317.
- Werner, T.L., Agarwal, N., Carney, H.M. & Rodgers, G.M. (2007) Management of cancer-associated thrombotic microangiopathy: what is the right approach? *American Journal of Hematology*, **82**, 295–298.
- Willis, M.S. & Bandarenko, N. (2005) Relapse of thrombotic thrombocytopenic purpura: is it a continuum of disease? *Seminars in Thrombosis and Hemostasis*, **31**, 700–708.
- Yarranton, H., Cohen, H., Pavord, S.R., Benjamin, S., Hagger, D. & Machin, S.J. (2003) Venous thromboembolism associated with the management of acute thrombotic thrombocytopenic purpura. *British Journal of Haematology*, **121**, 778–785.
- Yarranton, H., Lawrie, A.S., MacKie, I.J., Pinkoski, L., Corash, L. & Machin, S.J. (2005) Coagulation factor levels in cryosupernatant prepared from plasma treated with amotosalen hydrochloride (S-59) and ultraviolet A light. *Transfusion*, **45**, 1453–1458.
- Zakarija, A., Kwaan, H.C., Moake, J.L., Bandarenko, N., Pandey, D.K., McKoy, J.M., Yarnold, P.R., Raisch, D.W., Winters, J.L., Raife, T.J., Cursio, J.F., Luu, T.H., Richey, E.A., Fisher, M. J., Ortel, T.L., Tallman, M.S., Zheng, X.L., Matsumoto, M., Fujimura, Y. & Bennett, C.L. (2009) Ticlopidine- and clopidogrel-associated thrombotic thrombocytopenic purpura (TTP): review of clinical, laboratory, epidemiological, and pharmacovigilance findings (1989–2008). *Kidney International Supplement*, **2**, 0–S24.
- Zheng, X.L., Kaufman, R.M., Goodnough, L.T. & Sadler, J.E. (2004) Effect of plasma exchange on plasma ADAMTS13 metalloprotease activity, inhibitor level, and clinical outcome in patients with idiopathic and nonidiopathic thrombotic thrombocytopenic purpura. *Blood*, **103**, 4043–4049.