

Guidelines for the diagnosis and management of hereditary spherocytosis – 2011 update

Paula H. B. Bolton-Maggs,¹ Jacob C. Langer,² Achille Iolascon,³ Paul Tittensor⁴ and May-Jean King⁵

¹University of Manchester, Manchester, UK, ²Hospital for Sick Children, University of Toronto, Toronto, Canada, ³University Federico II of Naples, Naples, Italy, ⁴Patient Representative, Crewe, Cheshire, and ⁵NHS Blood and Transplant, Bristol, UK

Summary

Guidelines on hereditary spherocytosis (HS) published in 2004 (Bolton-Maggs *et al*, 2004) are here replaced to reflect changes in current opinion on the surgical management, (particularly the indications for concomitant splenectomy with cholecystectomy in children with mild HS, and concomitant cholecystectomy with splenectomy in those with asymptomatic gallstones). Further potential long term hazards of splenectomy are now recognised. Advances have been made in our understanding of the biochemistry of the red cell membrane which underpins the choice of tests. Biochemical assays of membranes proteins and genetic analysis may be indicated (rarely) to diagnose atypical cases. The diagnostic value of the eosin-5-maleimide (EMA) binding test has been validated in a number of studies with understanding of its limitations.

Keywords: spherocytosis, hereditary, splenectomy, child, erythrocyte membrane.

The guideline group was selected to represent UK medical experts and patient representatives but sought the expertise of two overseas specialists with a particular interest in hereditary spherocytosis (HS).

The writing group searched PubMed from 2003 to July 2010 for relevant literature including meta-analyses (none found), reviews and original papers in any language, using the following key words and combinations of them: hereditary spherocytosis; red cell membrane; spectrin; ankyrin; band 3; spherocytes; haemolysis; folate; folic acid; splenectomy; cholecystectomy; cholecystostomy; laparoscopic; gallstones; pneumococcal; vaccination; penicillin prophylaxis. Only the abstracts were read of papers in languages other than English. The writing group produced the draft guideline, which was subsequently revised by consensus by members of the General

Haematology Task Force of the British Committee for Standards in Haematology (BCSH). The guideline was then reviewed by a sounding board of approximately 50 UK haematologists, the BSCH and the British Society for Haematology Committee and comments incorporated where appropriate. The 'GRADE' system was used to quote levels and grades of evidence, details of which can be found in Appendix I. The objective of this guideline is to provide healthcare professionals with clear guidance on the management of HS. In all cases individual patient circumstances may dictate an alternative approach.

Summary of key recommendations

Diagnostic testing (confirmation of previous guidelines)

- 1 Newly diagnosed patients with a family history of HS, typical clinical features and laboratory investigations (spherocytes, raised mean corpuscular haemoglobin concentration [MCHC], increase in reticulocytes) do not require any additional tests (grade 1 recommendation, grade A evidence).
- 2 If the diagnosis is equivocal, a screening test with high predictive value for HS is helpful. The recommended screening tests are the cryohaemolysis test and EMA binding (grade 1 recommendation, grade A evidence). (Confirmation).
- 3 Gel electrophoresis analysis of erythrocyte membranes is the method of choice for diagnosis of atypical cases.

Recommendations for surgery (updated with major changes)

- 1 **The laparoscopic approach to splenectomy is recommended, but is dependent on the availability of appropriately trained surgeons, and suitable equipment (grade 1 recommendation, grade B evidence).**
- 2 **Partial splenectomy may be beneficial but needs further follow-up studies (grade 2 recommendation, grade C evidence).**

Correspondence: Dr. Paula H. B. Bolton-Maggs, c/o BCSH Secretary, British Society for Haematology, 100 White Lion Street, London, N1 9PF, UK. E-mail: Paula.Bolton-Maggs@manchester.ac.uk, bcsh@b-s-h.org.uk

First published online 5 November 2011
doi:10.1111/j.1365-2141.2011.08921.x

- 3 In children undergoing splenectomy, the gall bladder should be removed concomitantly if there are symptomatic gallstones. If stones are an incidental finding without symptoms, the value of cholecystectomy remains controversial. If the gallbladder is left *in situ*, including cases when a cholecystostomy with stone extraction is done, close follow-up using ultrasound is necessary (grade 2 recommendation, grade C evidence).
- 4 In children who require cholecystectomy for symptoms of gallstones, the use of concurrent splenectomy is controversial. It may be associated with a decreased future risk of common bile duct stones, but is associated with a risk of post-splenectomy sepsis (grade 2 recommendation, grade C evidence)
- 5 When splenectomy is indicated, ideally it should be done after the age of 6 years (grade 2 recommendation, grade C evidence).
- 6 There is no indication for extended thrombosis prophylaxis after splenectomy in patients with HS. Adults should receive perioperative thromboprophylaxis in the usual way.
- 7 Splenectomy should be avoided in patients with some forms of hereditary stomatocytosis (grade 1 recommendation, grade B evidence) due to an increased risk of venous thromboembolism.

The biochemical basis of HS

HS is a disease involving five membrane proteins that are in close contact with each other in the red cell membrane.

Organization of red blood cell membrane

The human red cell membrane consists of an outer lipid bilayer (cholesterol and phospholipids) and an inner layer of cytoplasmic spectrin-based cytoskeleton (covering about 65% of red cell surface). These two layers have no direct contact with each other (Fig 1). The current working hypothesis is that the concerted movements of the lipid bilayer and cytoskeleton proteins in the vertical and horizontal directions regulate both the deformability and elasticity of red blood cells (RBCs) in circulation. In addition to the known band 3 tetramer-ankyrin complex, a band 3-adducin-spectrin complex has recently been identified (Anong *et al*, 2009).

Biochemical abnormalities associated with HS

Detachment of the lipid bilayer from the spectrin-based cytoskeleton results in weakening of the vertical interaction, caused by either a deficiency or dysfunction of one or more of band 3, protein 4.2, ankyrin, and α and β spectrin proteins (Delaunay, 2007; Perrotta *et al*, 2008). The subsequent reduction in surface-to-volume ratio results in spherocytic red cells, which are osmotically fragile and are selectively trapped in, and removed by, the spleen, which consequently plays a pivotal role in the clinical features of this disease. Single or combined protein deficiency in the red cells can be determined by sodium dodecyl sulphate (SDS)-polyacrylamide gel electrophoresis (PAGE) (Table I). Patients with a severe single membrane protein deficiency or an imbalance with combined protein deficiencies (most commonly band 3 and ankyrin defects)

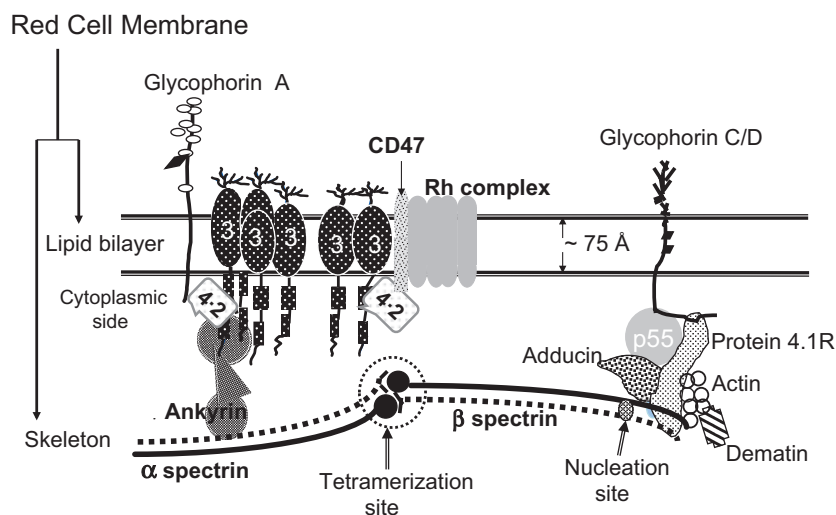


Fig 1. Schematic presentation of the structural organization of red cell cytoskeleton. Band 3 exists as both dimers and tetramers. On the cytoplasmic side of the red cell membrane, α spectrin binds to β spectrin to form the $\alpha\beta$ heterodimer. The band 3 macro-complex, associated with the frequently encountered membrane abnormalities in HS, is depicted in a greater detail than the Protein 4.1R complex (consisting of GPC and Protein 4.1R) (Mohandas & Gallagher, 2008). Band 3 exists as both dimers and tetramers in the red cell membranes. Spectrin exists predominantly as tetramers *in situ* although higher oligomers are also present. In addition to the known band 3 tetramer-ankyrin complex, a band 3-adducin-spectrin complex has recently been identified (Anong *et al*, 2009).

Table I. Types of mutations in membrane protein genes associated with HS and the observed membrane protein defects detected by SDS-PAGE.

Protein	Gene	Mutations detected (No. identified)*	Selected examples of partial protein deficiency (SDS-PAGE)	Primary defect in protein or gene
α Spectrin	<i>SPTA1</i>	Splicing/skipping (1) – Sp α^{LEPRA} allele	(i) α spectrin deficiency (ii) Marked deficiency of spectrin (α and β) with normal parents	(i) A variety of molecular defects (ii) Severe ndHS due to low expression allele Sp α^{LEPRA} inherited in <i>trans</i> to a Sp $^{\text{HS}}$ allele
β Spectrin	<i>SPTB</i>	Null mutations (10) Nonsense or in non-coding sequence (10) Missense (5) Polymorphism (1)	β spectrin deficiency	<i>SPTB</i> null mutations (silencing of one β -spectrin allele)
Ankyrin	<i>ANK1</i>	Frameshift (17) Nonsense (8) Abnormal splicing (4) Missense (4) Promoter region (2)	(i) Combined spectrin and protein 4.2 deficiency (ii) Ankyrin and spectrin deficiency† (iii) Ankyrin deficiency (recessive HS)	(i) Missing one haploid set of <i>ANK1</i> (ii) <i>ANK1</i> mutations (iii) <i>ANK1</i> : mutations in promoter in <i>trans</i> to mutations in coding sequence
Band 3	<i>SLC4A1</i>	Missense (23) Nonsense/frameshift (18) Larger mutant protein (3) Polymorphism (5)	Band 3 deficiency (partial reduction of band 6 also noted in some HS)	Instability of mutant band 3 mRNA or inability to incorporate predicted mutant band 3 protein
Protein 4.2	<i>EPB42</i>	Missense (4) Nonsense or deletion (3) Splicing (2)	(i) Complete protein 4.2 deficiency (null phenotype) (ii) Partial protein 4.2 deficiency	(i) Most often <i>EPB42</i> mutation (ii) Band 3 mutations resulting in loss of protein 4.2 binding site

*Mutations have been listed (Bolton Maggs & King, 2006)

†A reduction in ankyrin content due to *ANK1* mutation can be masked by reticulocytosis associated with increased haemolysis in HS. Thus sodium dodecyl sulphate polyacrylamide gel electrophoresis (SDS-PAGE) cannot detect ankyrin deficiency in erythrocyte membranes from non-splenectomized HS patients.

exhibit more severe haemolytic anaemia (Rocha *et al*, 2010a). Partial spectrin deficiency is likely to cause a moderate to severe clinical phenotype when compared with reductions in other membrane proteins. The clinical expression of HS is relatively uniform within a given family, but disease severity varies considerably between families. In a recent study of 300 HS patients, spectrin deficiency was the most frequent membrane defect (based on SDS-PAGE analysis and not DNA analysis of membrane genes) in those diagnosed in childhood whereas band 3 deficiency was the one found most in patients diagnosed during adulthood (Mariani *et al*, 2008). Gilbert syndrome (defined by a bilirubin concentration of 17–102 $\mu\text{mol/l}$) is a recognized cause of variability of hyperbilirubinaemia and gallstone formation within families. Determination of the *UGT1A1* promoter polymorphism [(TA)₇] is associated with increased bilirubin levels due to reduced transcription of the enzyme, and when inherited with HS may give a false impression of severity of haemolysis (Iolascon *et al*, 1998). Compound heterozygosity for this can also increase the risk of developing gallstones in HS children (Miraglia del Giudice *et al*, 1999; Rocha *et al*, 2010b).

Isolated red cell disorders due to band 3 mutations in the anion transport domain. Mutations affecting the anion transport function of band 3 can exacerbate the clinical features of some HS patients whose severe chronic haemolytic anaemia is not compatible with the small reduction of band 3 protein detected by SDS-PAGE. This subset of HS patients is designated as ‘spherocytosis with low temperature leak’ (SphLTL) (Bruce *et al*, 2005) and their band 3 mutations occur within exon 17 of *SLC4A1*, which encodes amino acids forming a part of the anion transport domain. The red cells from SphLTL patients have a concomitant reduction in monovalent cation (Na⁺/K⁺) transport because the mutant band 3 protein becomes an unregulated cation transporter (Bruce, 2008). Some patients in this subset may also have pseudohyperkalaemia.

Molecular genetics of HS

The genes encoding membrane proteins of the red cell cytoskeleton and their respective chromosomal locations are known (Table I). Autosomal dominant HS is often found to have primary mutations in the genes encoding ankyrin (*ANK1*),

band 3 (*SLC4A1*) or β spectrin (*SPTB*). Mutations in these three genes can lead to a secondary protein deficiency. *EPB42* mutations are more prevalent among the Japanese population.

Most of the reported protein gene mutations in HS are 'private' or sporadic occurrences, i.e. they are specific to one family or found in a few families from different countries. Knowledge of the gene mutation does not influence the clinical management of the patient but analysis of the mutant protein gene in family studies can clarify one of the following conditions.

The Sp α ^{LEPRA} allele (LEPRA: Low Expression PRAGue) is prevalent among non-dominant HS (nd-HS) (Boivin *et al*, 1993; Dhermy *et al*, 2000; Wichterle *et al*, 1996). This allele remains silent when inherited by a normal individual. However, mutations in the α spectrin gene (*SPTA1*), both homozygous and compound heterozygous (co-inherited with a pathogenic HS allele), result in severe HS with very low spectrin levels in the red cells (Tse *et al*, 1997).

De novo mutations are mostly found in recessive HS associated with *ANK1* and *SPTB*. The transmission of these ankyrin mutations to subsequent generations occurs in a dominant manner. A recurrent frameshift mutation, Ankyrin Florianópolis, has been found in three unrelated probands with severe dominant HS from different genetic backgrounds (Gallagher *et al*, 2000).

In the case of *SLC4A1* defects, additive effects of two unequally expressed *SLC4A1* mutant alleles can aggravate the clinical features of an affected individual (Alloisio *et al*, 1996, 1997; Bracher *et al*, 2001). The mutations associated with band 3 are heterogeneous with no apparent founder effect.

Clinical features and diagnosis

The clinical severity of HS varies from symptom-free carrier to severe haemolysis. Mild HS can be difficult to identify because individuals may have normal haemoglobin and bilirubin concentrations. The presence of spherocytes and a reticulocytosis will support the diagnosis. If there are no spherocytes seen on the film, no abnormalities in the red cell indices, and the reticulocyte count is normal, then a 'carrier' state cannot be excluded, but the individual is unlikely to have any clinical sequelae. Occasionally mild HS can be exacerbated by illnesses that cause splenomegaly, such as infectious mononucleosis. It is important to consider other possible diagnoses for chronic haemolysis if the blood smear appearances are not typical, particularly congenital dyserythropoietic anaemia type II (CDAIL). Several cases have been misdiagnosed in the past, with the correct diagnosis being established only when they fail to respond as expected to splenectomy (Iolascon *et al*, 2001).

Age at diagnosis

Although the diagnosis of HS is often made in childhood and young adult life, it may be diagnosed at any time of life including old age (Bolton-Maggs *et al*, 2004).

Clinical features

The diagnosis of HS is generally straightforward (Bolton-Maggs *et al*, 2004).

Diagnosis in the neonate. Neonatal jaundice is common and may require exchange transfusion, but is not clearly related to the subsequent severity of the HS. The diagnosis of HS in neonates may be difficult (Schroter & Kahsnitz, 1983). The film appearances may not be typical, and the osmotic fragility (OF) test is unreliable. New studies show that an MCHC of >360 g/l in neonates is a useful indicator for HS (82% sensitivity and 98% specificity) (Christensen & Henry, 2010). The use of tests for red cell dehydration and reduced red cell deformability demonstrated that four in 402 jaundiced neonates had HS (Saada *et al*, 2006), suggesting a higher HS incidence (1%) among this selected group of neonates with jaundice than the reported incidence for a general population (1 in 2000 to 1 in 5000). The mechanism for this is not clearly understood but the inability of HbF to bind free 2,3-diphosphoglycerate (2,3-DPG) may cause a destabilizing effect of 2,3-DPG on the spectrin-protein 4.1 interaction (Pinto *et al*, 1995). Haematologists need to advise potential parents of the risk of neonatal jaundice, as occasionally exchange transfusion has been required for severe hyperbilirubinaemia. There may be an interval of several days before the bilirubin reaches its peak, so infants born to parents with known HS should be carefully monitored over several days.

Some neonates with HS may be transfusion-dependent due to their inability to mount an adequate erythropoietic response in the first year of life (Delhommeau *et al*, 2000). Continued transfusion-dependence is unusual and it is important to avoid repeated transfusion where possible. Erythropoietin may be of benefit in reducing or avoiding transfusion, and can usually be stopped by the age of 9 months (Tchernia *et al*, 2000). Many older children with Hb levels of 50–60 g/l do not require transfusion. Children requiring one or two transfusions early in life frequently become transfusion independent.

As the morphology may be unclear in the neonate, other diagnoses may be considered (Bolton-Maggs *et al*, 2004). Infantile pyknotocytosis should be considered when an infant (usually pre-term) presents with transient haemolytic anaemia (6–9 months after birth), reticulocytosis and hyperbilirubinaemia. The blood film shows distorted densely stained red cells (pyknotocytes). After blood transfusion, the transfused normal red cells may become distorted (Eyssette-Guerreau *et al*, 2006; Tuffy *et al*, 1959). This transient haemolytic anaemia of no known aetiology resolves 6–9 months after birth without further intervention.

CDAIL (recessive inheritance with haemolysis with increased OF) should be considered in the differential diagnosis because it may be misdiagnosed as HS and does not respond as satisfactorily to splenectomy.

Co-inheritance of other haematological disorders. Disorders such as beta thalassaemia trait or sickle cell disease, can lead to confusion in the diagnosis and variable clinical effects. Iron, folate or vitamin B12 deficiency can mask the laboratory features. Obstructive jaundice alters the lipid composition of the red cell membrane, masking the red cell morphology, and reducing haemolysis.

Family history. Most cases (75%) will have a family history of HS. In clear-cut cases (typical history and physical findings, spherocytes on the blood film with a reticulocytosis and negative direct antiglobulin test) there is no indication to perform further special laboratory tests. In the absence of a family history the most important differential diagnosis is autoimmune haemolytic anaemia (AIHA) (rare in children, but can follow a viral infection and is usually transient). Usually (but not always) AIHA can be excluded by a negative direct antiglobulin test. Other membrane abnormalities must be considered if the morphology is atypical, and in these, further investigations may be required.

Individual clinical features

Anaemia. The severity of anaemia reflects the severity of haemolysis and spleen size. Many individuals have compensated haemolysis with a normal haemoglobin concentration (Hb) but a reticulocytosis. During pregnancy some non-splenectomized HS patients develop sufficiently severe anaemia to need blood transfusion.

Erythropoietin may be of benefit in reducing or avoiding transfusion in neonates and can usually be stopped by the age of 9 months (Tchernia *et al*, 2000). Older individuals have an erythropoietin level higher than normal (Rocha *et al*, 2005). Many older children with Hb levels of 50–60 g/l do not require transfusion. Children requiring one or two transfusions early in life frequently become transfusion independent.

Splenomegaly. Most children and adults with HS have mild to moderate enlargement of the spleen, but other than assisting in the diagnosis, this is of little clinical significance. The size of

the spleen *per se* is not an indication for splenectomy. There is no evidence from the literature that splenic rupture is commoner than in the normal population. There is also no evidence in support of limiting activity in children with splenomegaly due to HS.

Criteria for disease severity have been previously defined (Eber *et al*, 1990) and are shown in Table II.

Laboratory investigation

The laboratory diagnosis is usually straightforward and is based upon a combination of clinical history, family history, physical examination (splenomegaly, jaundice) and laboratory data (full blood count, morphology and reticulocyte count) (Table IV in Bolton-Maggs *et al*, 2004). Additional testing for confirmation of HS is indicated when the diagnostic criteria are not met, and other causes of haemolysis have been excluded. For instance, the film appearances are atypical, there is no clear pattern of inheritance, or the proband has an ongoing mild haemolytic process with an apparently normal full blood count.

The recommended laboratory tests are the EMA binding test or the cryohaemolysis test. The OF test is not recommended for routine use (Bolton-Maggs *et al*, 2004).

EMA binding test and other useful screening tests

The EMA binding test uses flow cytometry to determine the amount of fluorescence (reflecting EMA bound to specific transmembrane proteins) derived from individual red cells (King *et al*, 2004). If the majority of the patient's red cells are phenotypically normal without significant loss of the EMA-binding membrane proteins (as in the case of mildly affected HS), the fluorescence results obtained may be indeterminate. Such individuals are more easily identified in a family study. The question is whether these near-normal results are of any clinical significance. The EMA binding test is easy to use, and test results are available for reporting in 2–3 h. It has comparable specificity and sensitivity to the acidified glycerol lysis test (Stoya *et al*, 2006) and ektacytometry (a test not

Table II. Classification of spherocytosis and indications for splenectomy (modified from Eber *et al*, 1990 (copyright 1990 Elsevier).

Classification	Trait	Mild	Moderate	Severe
Haemoglobin (g/l)	Normal	110–150	80–120	60–80
Reticulocyte count, %	Normal (<3%)	3–6	>6	>10
Bilirubin ($\mu\text{mol/l}$)	<17	17–34	>34	>51
Spectrin molecules per erythrocyte (% of normal)*	100	80–100	50–80	40–60
Splenectomy	Not required	Usually not necessary during childhood and adolescence	Necessary during school age before puberty	Necessary – delay until 6 years if possible

*Data on spectrin content are provided for interest. This quantitation involves complex procedures.

Normal (mean \pm SD): $226 \pm 54 \times 10^3$ Sp molecules per cell.

readily available) (Girodon *et al*, 2008) and is better than the OF test (Kar *et al*, 2010).

In a general laboratory, the EMA binding test can be used in differential diagnosis for hereditary stomatocytoses (used in conjunction with OF test) and hereditary pyropoikilocytosis (HPP, severe hereditary elliptocytosis) (Table III). If the test results are consistent with the clinical presentation, there is the choice of whether or not to proceed with confirmatory tests (carried out by specialized laboratories).

When HS is suspected in a neonate, if the baby is well, testing can be postponed until the child is at least 6 months of age or older when the morphology may be less confusing. The EMA test will be positive irrespective of morphology and age of the neonate. Other membrane abnormalities must be considered if the morphology is atypical, and in these, further investigations may be required. The reticulocyte count in CDAII is not as high as in HS. SDS-PAGE of red cell membrane proteins reveals the characteristic compact CDAII band 3 protein abnormality. This differential diagnosis is important because in CDAII splenectomy is less effective and does not completely resolve the clinical symptoms.

Several laboratory tests can detect typical HS (Table III). However, these can give false positive results for a wide spectrum of clinical conditions and rare red cell disorders unrelated to cytoskeleton defects (Table VI in Bolton-Maggs *et al*, 2004). Therefore caution is required when a positive test result for HS is not compatible with the clinical presentation and red cell morphology.

A normal OF test does not exclude the diagnosis of HS and may occur in 10–20% of cases (Bolton-Maggs *et al*, 2004).

The acid glycerol lysis test (AGLT) has a higher detection rate in asymptomatic relatives of known affected individuals

than the OF test (Mariani *et al*, 2008). The drawback of both tests is an apparent lack of specificity under certain circumstances (Table VI in Bolton-Maggs *et al*, 2004). However, laboratories with long-standing experience in using the AGLT have found that the sensitivity can be greater than for the EMA binding test (Mariani *et al*, 2008).

Tests for differentiating HS from other rare membrane-associated disorders

These have been discussed in the previous guideline (Bolton-Maggs *et al*, 2004) and are summarized in Table III.

Recommendations

A suggested diagnostic pathway is shown in Fig 2

- 1 Newly diagnosed patients with a family history of HS, typical clinical features (splenomegaly) and laboratory investigations (spherocytes, raised MCHC, increase in reticulocytes) do not require any additional tests (grade 1 recommendation, grade A evidence).**
- 2 If the diagnosis is equivocal, e.g. where there are a few spherocytes on the film but no other laboratory, clinical or family evidence, a screening test with high predictive value for HS is helpful. The recommended screening tests are the cryohaemolysis test and EMA binding test (grade 1 recommendation, grade A evidence). The high predictive value of both techniques for the diagnosis of HS can be improved further when the results are reviewed in conjunction with clinical information, family history and red cell indices. If the interpretation of the test result is**

Table III. Application of screening tests in the differential diagnosis of HS and other membrane-associated red cell disorders.

Diagnosis	Osmotic fragility test	Acid glycerol lysis-time test	Osmotic gradient ektacytometry	Cryohaemolysis Test	EMA binding test*
HS	↑ Fragility	Shortened lysis time	Distinct HS profile	↑ Lysis	↓ Fluorescence
AIHA	↑ Fragility	Shortened lysis time	Similar to HS	?	Normal or ↑ with some
Hereditary pyropoikilocytosis	?	?	?	?	↓↓ Fluorescence
Overhydrated HSt	↑ Fragility†	?	Distinct profile	?	↑ Fluorescence
Dehydrated HSt	↓ Fragility†	Normal lysis time†	Distinct profile	?	↑ Fluorescence
Cryohydrocytosis	?	?	Distinct profile	?	↓ Fluorescence
CDAII‡	↑ Fragility	?	?	Normal or ↑ with some	Normal or ↓ with some
SAO	?	?	Not deformable§	↑ Lysis	↓ Fluorescence

HS, hereditary spherocytosis; AIHA, autoimmune haemolytic anaemia; HSt, hereditary stomatocytosis; CDAII, congenital dyserythropoietic anaemia type II; SAO, South-East Asian ovalocytosis; EMA, eosin-5-maleimide.

?: No published data found.

*The EMA binding test can detect more than one sub-population of red cells in a peripheral blood sample (King *et al*, 2008).

†See the references (Nolan, 1984; Vives Corrons *et al*, 1995).

‡CDAII can be confirmed by molecular analysis of *SEC23B* (encoding COPII coat component) (Schwarz *et al*, 2009).

§SAO red cells give a virtually flat deformability profile (Ravindranath *et al*, 1994), indicating that these cells are rigid.

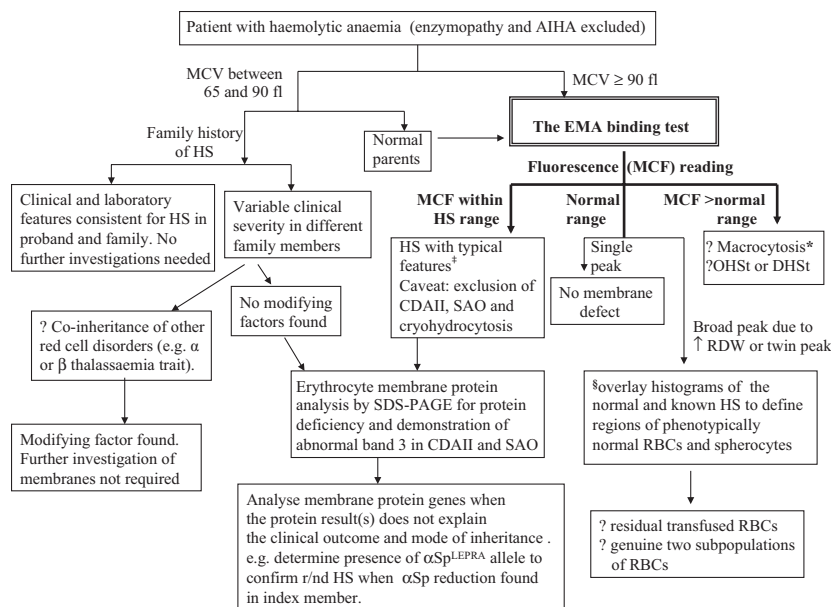


Fig 2. Flow chart for the diagnosis of HS. *Macrocytic red cells (mean corpuscular volume [MCV] ≥ 100 fl) give mean channel fluorescence (MCF) readings above the reference range for normal adults. The red cell disorders found to give such results are megaloblastic anaemia (Kar *et al*, 2010), overhydrated (OHSt) and dehydrated hereditary stomatocytosis (DHS), antibody/cold agglutinin coated red cells, CDA type I and pyruvate kinase deficiency. §Overlay of fluorescence histograms is to superimpose the histograms of normal control and a known HS (from archive) on to that of the test sample. This can assist the identification of microspherocytes, spherocytes, and phenotypically normal red cells (King *et al*, 2008). ‡See Table IV in Bolton-Maggs *et al* (2004). HS, hereditary spherocytosis; AIHA, autoimmune haemolytic anaemia; CD41, congenital dyserythropoietic anaemia type II; SAO, South-East Asian ovalocytosis; EMA, eosin-5-maleimide; RDW, red cell distribution width; RBCs, red blood cells; r/nd, recessive/non-dominant.

still equivocal, perform a family study to determine the trend (i.e. which family members also give results similar to the proband).

- Confirmation of diagnosis may be necessary in selected cases if the screening tests produce an equivocal or borderline result. Gel electrophoresis analysis of erythrocyte membranes is the method of choice. This technique is useful for determining the extent of membrane deficiency for the patient. The main drawback is a lack of sensitivity to very mild or asymptomatic 'carrier' HS.

The use of SDS-PAGE is recommended:

- When the clinical phenotype is more severe than predicted from the red cell morphology.
- When the red cell morphology is more severe than predicted from parental blood films where one parent is known to have HS.
- If the diagnosis is not clear prior to splenectomy, when a patient might have an abnormality in Na^+/K^+ permeability (as found in hereditary stomatocytosis). Where the morphology and red cell indices are typical for HS, there should be no doubt. In more subtle cases (when mean corpuscular volume [MCV] >100 fl), clarification is essential (Delaunay *et al*, 1999). Splenectomy may not be appropriate for the clinical management of those patients with the rare

overhydrated and dehydrated hereditary stomatocytosis (Stewart *et al*, 1996; Stewart & Turner, 1999) (grade 1 recommendation, grade B evidence).

- Diagnosis of HS does not require further investigation by molecular analysis of the affected genes.

Clinical management of individuals with HS

Folate therapy

Folate supplementation is recommended in severe and moderate HS but is not necessary in mild HS (Bolton-Maggs *et al*, 2004).

Routine observation and frequency of blood tests

An annual visit for a child with HS is sufficient once the baseline has been established and, in the absence of symptoms, a blood count at every visit is unnecessary. Growth should be monitored, and parents should be informed about the risk of sudden anaemia due to parvovirus infection. Children with severe HS should be closely monitored during other viral infections. Those receiving regular blood transfusions should have genotyped red cells. Adults with mild disease are not usually under regular follow-up but chronic anaemia will enhance iron absorption and co-inheritance of a haemochromatosis gene can lead to severe iron overload.

Clinical management of individuals with HS – surgery

This section has been significantly revised and replaces the recommendations in the previous guideline (Bolton-Maggs *et al*, 2004).

In which patients is splenectomy indicated? Splenectomy is very effective in reducing haemolysis, leading to a significant prolongation of the red cell life span (although not necessarily to normal) (Baird *et al*, 1971; Chapman & McDonald, 1968) (Grade B evidence). The clinical manifestations and complications (anaemia and gallstones) are much reduced in severe HS and abolished in milder cases but at the price of an increased risk of life-threatening sepsis from encapsulated organisms, particularly *Streptococcus pneumoniae*. Recent evidence demonstrates that splenectomy for HS in children is very safe in the short term with no deaths and infrequent complications (<1% in 1657 splenectomies) (Abdullah *et al*, 2009).

Patients should be selected for splenectomy on the basis of their clinical symptoms (Bolton-Maggs *et al*, 2004; Table II) and presence of complications such as gallstones, not simply on the basis of the diagnosis alone (grade 2 recommendation, grade C evidence). Splenectomy should be performed in children with severe HS, considered in those who have moderate disease, and should probably not be performed in those with mild disease. A careful history is important in those with moderate to mild disease to establish if there is evidence suggesting reduced exercise tolerance; the metabolic burden of increased marrow turnover may be considerable. Where there is a family history, the benefit of splenectomy in other individuals may help determine whether to proceed.

Infection risks and their management. Splenectomy is associated with a lifelong increased risk of overwhelming infection, particularly with pneumococcal species, which is not completely eliminated by pre-operative vaccinations and post-splenectomy antibiotic prophylaxis (Bolton-Maggs *et al*, 2004). Patients should be vaccinated according to national guidelines (Davies *et al*, 2011). No changes are made in the recommendations (Bolton-Maggs *et al*, 2004). National recommendations vary and this subject has been recently reviewed (Price *et al*, 2007). It is important to keep searching for previously splenectomized adults (e.g. relatives of current HS patients) who are unlikely to have been fully protected (due to changes in vaccination policy and emergence of more effective vaccines) and who may not know that they are at risk (Grace *et al*, 2009).

Recommendations

1 Patients and parents should be informed about the lifelong small risk of overwhelming sepsis after splenectomy, and provided with a splenectomy card (grade 1 recommendation, grade B evidence).

2 National guidelines for immunization should be followed (Davies *et al*, 2011). The need for reimmunization and its frequency are unclear as are the optimal duration of postsplenectomy antibiotic prophylaxis and choice of drug (grade 2 recommendation, grade C evidence).

Which surgical approach should be used? *Laparotomy:* The traditional approach to splenectomy has been total, by laparotomy, through either an upper midline incision or, more usually, a left sub-costal approach. The spleen has been removed in its entirety and a careful search made for any splenunculi (accessory splenic tissue) on the assumption that any splenic tissue left behind could lead to a recurrence of symptomatic anaemia. There are no studies that have quantified this risk, although it has been reported (Mackenzie *et al*, 1962).

Laparoscopic splenectomy: The traditional approaches are being challenged by the advent of laparoscopy. Either a supine or lateral approach can be used and the splenic vessels are divided using a harmonic scalpel, Ligasure™ device, clips or surgical stapler. The spleen is caught in a specimen bag introduced through a port site, and morcellated inside the bag so that the contents can be removed through the port. In cases of massive splenomegaly, the spleen may not fit into the bag and must be removed through an open incision. A transverse lower abdominal incision is usually used in this situation. Laparoscopic cholecystectomy may be performed at the same time (Farah *et al*, 1997). There are no published randomized trials comparing laparoscopic to open splenectomy in children, though there are a large number of case series outlining experience with laparoscopic splenectomy, either on its own (Rescorla *et al*, 2002; Smith *et al*, 1994; Tanoue *et al*, 2002) (Minkes *et al*, 2000) or in combination with cholecystectomy (Caprotti *et al*, 1999). Each of these is a descriptive study and compares the outcomes of an institution's experience against either historical data from the same institution or reported results from other institutions. Published results suggest that the laparoscopic approach is both feasible and safe (Danielson *et al*, 2000), and is associated with a shorter hospital stay, faster time to feeding, and less pain. Laparoscopic splenectomy is more difficult in the presence of significant splenic enlargement (Bagdasarjian *et al*, 2000) so that a preoperative assessment of splenic size by ultrasound is recommended (Esposito *et al*, 1998). Laparoscopic splenectomy should be the preferred approach for surgeons who have the necessary equipment, training and experience to carry out these procedures safely.

Partial splenectomy: Concern over the possible consequences of sepsis has led some groups to investigate whether it is necessary to remove the whole spleen to control haemolysis. Partial splenectomy can improve transfusion-dependent children with very severe HS while theoretically preserving some splenic function as protection against sepsis (grade B evidence). A number of reports have been published (Bader-Meunier *et al*, 2001; Tchernia *et al*, 1997, 1993). Forty patients

were followed for 1–14 years; the majority remained symptom-free though three patients subsequently required total splenectomy for further symptomatic anaemia (Bader-Meunier *et al*, 2001), but only 17 of 40 patients had completed at least 5 years follow-up and a further five were lost to follow-up. It is too early to determine whether others will need total splenectomy. The phagocytic function of the spleen was sustained (demonstrated by technetium 99 m scans) and there were no reports of serious infection. Because there is currently no accurate way to determine the ability of the spleen to participate in humoral defence, these patients were immunized and continued on postoperative anti-bacterial prophylaxis. Another group have also reported favourable results in 16 children with HS followed for up to 6 years after partial splenectomy (Rice *et al*, 2003). Both of these series are small, and have been followed for too short a time to know if this procedure reduces risks of post-splenectomy sepsis. A further caution is that four of 18 patients developed new gallstones, after sub-total splenectomy. A recent larger multicentre study of 62 children documented excellent resolution of symptoms and improvement of anaemia, with fewer than 5% of the patients requiring subsequent completion splenectomy (Buesing *et al*, 2011).

Several groups have now reported the use of laparoscopic partial splenectomy in patients with HS, leaving behind either the upper or lower pole (Dutta *et al*, 2006; Vasilescu *et al*, 2006). In the short term, the postoperative course does not appear to be as favourable as seen with laparoscopic total splenectomy, in terms of pain management or hospital stay (Morinis *et al*, 2008). Longer follow-up will be necessary to determine if the outcomes after laparoscopic partial splenectomy are equivalent to those using an open technique.

Should a concurrent cholecystectomy be performed? In children with no evidence of cholelithiasis, there is no indication to remove the gall bladder at the time of splenectomy. Once the spleen is removed, individuals with HS do not develop pigment stones. In the absence of stones, splenectomy alone is sufficient – a review of 17 patients who had undergone splenectomy without cholecystectomy (gall stones excluded pre- or peri-operatively) under the age of 18 years demonstrated that none developed any evidence of cholelithiasis (clinical or sub clinical) over a mean follow-up of 15 years (Sandler *et al*, 1999).

Stones are reported to be present in 21–63% of patients with HS (Rutkow, 1981). Symptoms of cholelithiasis remain a prime reason for carrying out a splenectomy in HS. A significant number of children with HS develop pigment stones in the first decade of life. The risk is increased in individuals who co-inherit Gilbert syndrome with HS, with a five-fold increased risk of developing gallstones (Miraglia del Giudice *et al*, 1999) (grade B evidence). An Italian survey of 468 children with HS showed that 79 had gallstones, about half of them diagnosed before the age of 11 years (Pinto *et al*, 1995). A study of 103 unsplenectomized children recom-

mended ultrasound (rather than conventional radiographs) as the optimal method to detect stones with an accuracy of 95% (Miraglia del Giudice *et al*, 1999). Regular ultrasound examination of the biliary system from the age of about 5 years may identify individuals more likely to have troublesome symptoms later in life, and who may benefit from splenectomy prior to puberty (grade 2 recommendation, grade C evidence).

It is not clear whether adults with mild HS should be regularly screened by ultrasound for asymptomatic gallstones, particularly as it is not clear whether these should be removed. One study of 123 adults with silent stones (not in relation to haemolytic conditions) found that only 15–20% developed symptoms over a prolonged follow-up (Gracie & Ransohoff, 1982). However, there are no good longitudinal studies of the outcome in children with silent stones if left alone. One study of children with non-pigmented stones suggested that asymptomatic stones should be managed expectantly (Bruch *et al*, 2000). Another study has shown chronic inflammatory changes in the gall bladder mucosa in individuals with asymptomatic stones (Csendes *et al*, 1998). There are no clear data on the management of asymptomatic gallstones in children undergoing splenectomy for HS. Some authors have suggested that all patients with stones, even the asymptomatic ones, should undergo cholecystectomy (Gotz *et al*, 1977), and this has become the most common approach by paediatric surgeons. However, there is evidence to suggest that in young children removal of stones without cholecystectomy may be sufficient after splenectomy. The rationale behind this is that the risk of stones is markedly reduced after splenectomy and there is evidence that cholecystectomy may lead to alterations in bile salt metabolism that predispose to colon carcinoma later in life (Shao & Yang, 2005). Robertson *et al* (1988) reported on the clinical and ultrasound follow-up of five children with HS who had cholecystectomy with stone removal at the time of splenectomy. In four of the cases there were no stones, but in one there was an asymptomatic stone discovered. However, the follow-up period was short (1–2 years), and there have been no further reports of systematic follow-up of this cohort. In both adults and children who do not undergo cholecystectomy, regular follow-up should include assessment of possible symptoms (typical and atypical) suggestive of gall bladder disease.

There is general consensus that individuals with symptomatic gallstones should undergo cholecystectomy, although there are no randomized trials examining this question. The opposite question, whether the spleen should be removed in children with mild HS who have symptomatic gallstones, remains controversial. A recent study of 16 children who had cholecystectomy without splenectomy for mild HS reported that only three subsequently required splenectomy (within 2–5 years). The follow-up of the other 13 was 0.5–10.6 years (Alizai *et al*, 2010). This and other questions could be answered by well-designed observational studies, although they would have to be multi-centred.

Recommendations

- 1 **The laparoscopic approach to splenectomy is associated with less pain, shorter hospital stay and better cosmetic appearance, but is dependent on the availability of appropriately trained surgeons, and suitable equipment (grade 1 recommendation, grade B evidence).**
- 2 **Partial splenectomy is theoretically associated with a decreased risk for post-splenectomy sepsis, but it is possible that further surgery may need to be undertaken for either recurrence of haematological problems or for symptomatic cholelithiasis (grade 2 recommendation, grade C evidence).**
- 3 **In children undergoing splenectomy, the gall bladder should be removed concomitantly if there are symptomatic gallstones. If stones are an incidental finding without symptoms, the value of cholecystectomy remains controversial. If the gallbladder is left *in situ* (including when a cholecystostomy with stone extraction has been done), close follow-up using ultrasound is necessary (grade C evidence, grade 2 recommendation).**
- 4 **In children who require cholecystectomy for symptoms of gallstones, the use of concurrent splenectomy is controversial. It may be associated with a decreased risk of common bile duct stones in the future, but is also associated with a risk of post-splenectomy sepsis (grade 2 recommendation, grade C evidence)**
- 5 **When splenectomy is indicated, ideally it should be done after the age of 6 years (grade 2 recommendation, grade C evidence).**

What is the risk of late post-splenectomy thrombosis? Adults undergoing splenectomy should receive standard thromboprophylaxis where indicated. Splenectomy is usually followed by a reactive thrombocytosis that may be quite spectacular in children, with platelet counts rising to more than $1000 \times 10^9/l$ (Boxer *et al*, 1978; Coon *et al*, 1978; Hirsh & Dacie, 1966). Until recently, the available evidence suggested that the only individuals in whom there is an increased risk of late (i.e. not related to the surgery itself) thrombosis after splenectomy were those with myeloproliferative disorders (Gordon *et al*, 1978), or persisting anaemia with abnormal red blood cells (Hirsh & Dacie, 1966), and was demonstrated for beta thalassaemia intermedia (Cappellini *et al*, 2000) and for forms of hereditary stomatocytosis (Delaunay *et al*, 1999). It is therefore vital to differentiate these membrane disorders from HS and to avoid splenectomy. Thrombotic events have anecdotally been reported in patients with HS, (Hayag-Barin *et al*, 1998; Nikol *et al*, 1997) but the frequency of inherited thrombotic risk factors is high enough (particularly Factor V Leiden) in Northern Europeans that these will occur by chance in association with HS. However, there is now an increasing body of evidence (Crary & Buchanan, 2009) that splenectomy may be associated with a number of vascular complications

including pulmonary hypertension (Hoepfer *et al*, 1999) and an increased risk of atherosclerosis (Schilling *et al*, 2006, 2008). These factors should also be taken into account when deciding whether or not to proceed to splenectomy (Schilling, 2009).

Recommendations

- 1 **There is no indication for extended thrombosis prophylaxis after splenectomy in patients with HS. Adults should receive perioperative thromboprophylaxis in the usual way.**
- 2 **Splenectomy should be avoided in patients with some forms of hereditary stomatocytosis (grade 1 recommendation, grade B evidence).**

Conclusions

New studies of the EMA binding test have confirmed its diagnostic validity for HS in many routine laboratories. For many years making the diagnosis was usually followed almost automatically by splenectomy. The indications for splenectomy are clearer and classification of HS into clinically mild, moderate and severe groups is helpful. Splenectomy will be of benefit in all people with severe and some people with moderate HS, but is not usually necessary in mild cases. Our recommendations concerning partial splenectomy and concomitant splenectomy with cholecystectomy or cholecystectomy with splenectomy have been updated to reflect current opinion but further studies are required. Recently evidence is emerging that there may be adverse vascular long-term consequences of splenectomy. The final decision however, will rest on consultation between the family and clinician.

Disclaimer

While the advice and information in these guidelines is believed to be true and accurate at the time of going to press, neither the authors, the British Society for Haematology nor the publishers accept any legal responsibility for the content of these guidelines.

Acknowledgements

Paula Bolton-Maggs led the guideline writing and was responsible for editing the manuscript. May-Jean King contributed the biochemical and laboratory section, Jacob Langer contributed the section on surgical management, Achille Iolascon contributed the section on molecular genetics. Paul Tittensor contributed the patient view-point and his comments were integrated into the final manuscript. All authors have contributed to the editing, and approved the final version, which has also been approved by the BCSH General Haematology task force, and has been out to the sounding board of consultant haematologists in the UK. No financial support was received for this work.

Source of funding

None.

Conflict of Interest

None of the authors have received any funding from companies related to the disorder or its treatment.

Appendix I: Grading of Recommendations Assessment, Development and Evaluation (GRADE)

Strength of recommendation

Strong (grade 1): Strong recommendations (grade 1) are made when there is confidence that the benefits do or do not outweigh harm and burden. Grade 1 recommendations can be applied uniformly to most patients. Regard as 'recommend'.

Weak (grade 2): Where the magnitude of benefit or not is less certain a weaker grade 2 recommendation is made. Grade 2 recommendations require judicious application to individual patients. Regard as 'suggest'.

Quality of evidence and definitions

The quality of evidence is graded as high (A), moderate (B) or low (C). To put this in context it is useful to consider the uncertainty of knowledge and whether further research could change what we know or our certainty.

(A) *High:* Further research is very unlikely to change confidence in the estimate of effect. Current evidence derived from randomized clinical trials without important limitations.

(B) *Moderate:* Further research may well have an important impact on confidence in the estimate of effect and may change the estimate. Current evidence derived from randomized clinical trials with important limitations (e.g. inconsistent results, imprecision – wide confidence intervals or methodological flaws – e.g. lack of blinding, large losses to follow-up, failure to adhere to intention to treat analysis), or very strong evidence from observational studies or case series (e.g. large or very large and consistent estimates of the magnitude of a treatment effect or demonstration of a dose-response gradient).

(C) *Low:* Further research is likely to have an important impact on confidence in the estimate of effect and is likely to change the estimate. Current evidence from observational studies, case series or just opinion.

References

- Abdullah, F., Zhang, Y., Camp, M., Rossberg, M.I., Bathurst, M.A., Colombani, P.M., Casella, J.F., Nabaweisi, R. & Chang, D.C. (2009) Splenectomy in hereditary spherocytosis: review of 1,657 patients and application of the pediatric quality indicators. *Pediatric Blood Cancer*, **52**, 834–837.
- Alizai, N.K., Richards, E.M. & Stringer, M.D. (2010) Is cholecystectomy really an indication for concomitant splenectomy in mild hereditary spherocytosis? *Archives of Disease in Childhood*, **95**, 596–599.
- Alloisio, N., Maillet, P., Carre, G., Texier, P., Vallier, A., Baklouti, F., Philippe, N. & Delaunay, J. (1996) Hereditary spherocytosis with band 3 deficiency. Association with a nonsense mutation of the band 3 gene (allele Lyon), and aggravation by a low-expression allele occurring in trans (allele Genas). *Blood*, **88**, 1062–1069.
- Alloisio, N., Texier, P., Vallier, A., Ribeiro, M.L., Morle, L., Bozon, M., Bursaux, E., Maillet, P., Goncalves, P., Tanner, M.J., Tamagnini, G. & Delaunay, J. (1997) Modulation of clinical expression and band 3 deficiency in hereditary spherocytosis. *Blood*, **90**, 414–420.
- Anong, W.A., Franco, T., Chu, H., Weis, T.L., Devlin, E.E., Bodine, D.M., An, X., Mohandas, N. & Low, P.S. (2009) Adducin forms a bridge between the erythrocyte membrane and its cytoskeleton and regulates membrane cohesion. *Blood*, **114**, 1904–1912.
- Bader-Meunier, B., Gauthier, F., Archambaud, F., Cynober, T., Mielot, F., Dommergues, J.P., Warszawski, J., Mohandas, N. & Tchernia, G. (2001) Long-term evaluation of the beneficial effect of subtotal splenectomy for management of hereditary spherocytosis. *Blood*, **97**, 399–403.
- Bagdasarian, R.W., Bolton, J.S., Bowen, J.C., Fuhrman, G.M. & Richardson, W.S. (2000) Steep learning curve of laparoscopic splenectomy. *Journal of Laparoendoscopic & Advanced Surgical Techniques. Part A*, **10**, 319–323.
- Baird, R.N., Macpherson, A.I.S. & Richmond, J. (1971) Red-blood-cell survival after splenectomy in congenital spherocytosis. *Lancet*, **2**, 1060–1061.
- Boivin, P., Galand, C., Devaux, I., Lecomte, M.C., Garbarz, M. & Dhery, D. (1993) Spectrin alpha IIa variant in dominant and non-dominant spherocytosis. *Human Genetics*, **92**, 153–156.
- Bolton Maggs, P. & King, M.J. (2006) Hereditary spherocytosis, hereditary elliptocytosis and related disorders. In: *Clinical Hematology* (ed. by N.S. Young, S.L. Gerson & K.A. High), pp. 293–307. Mosby Elsevier, Philadelphia.
- Bolton-Maggs, P.H., Stevens, R.F., Dodd, N.J., Lamont, G., Tittensor, P. & King, M.J. (2004) Guidelines for the diagnosis and management of hereditary spherocytosis. *British Journal of Haematology*, **126**, 455–474.
- Boxer, M.A., Braun, J. & Emlen, L. (1978) Thromboembolic risk of postsplenectomy thrombocytosis. *Archives of Surgery*, **113**, 808–809.
- Bracher, N.A., Lyons, C.A., Wessels, G., Mansvelt, E. & Coetzer, T.L. (2001) Band 3 Cape Town (E90K) causes severe hereditary spherocytosis in combination with band 3 Prague III. *British Journal of Haematology*, **113**, 689–693.
- Bruce, L.J. (2008) Red cell membrane transport abnormalities. *Current Opinion in Hematology*, **15**, 184–190.
- Bruce, L.J., Robinson, H.C., Guizouarn, H., Borgese, F., Harrison, P., King, M.J., Goede, J.S., Coles, S.E., Gore, D.M., Lutz, H.U., Ficarella, R., Layton, D.M., Iolascon, A., Ellory, J.C. & Stewart, G.W. (2005) Monovalent cation leaks in human red cells caused by single amino-acid substitutions in the transport domain of the band 3 chloride-bicarbonate exchanger, AE1. *Nature Genetics*, **37**, 1258–1263.
- Bruch, S.W., Ein, S.H., Rocchi, C. & Kim, P.C. (2000) The management of nonpigmented gallstones in children. *Journal of Pediatric Surgery*, **35**, 729–732.
- Buesing, K.L., Tracy, E.T., Kiernan, C., Pastor, A.C., Cassidy, L.D., Scott, J.P., Ware, R.E., Davidoff, A.M., Rescorla, F.J., Langer, J.C., Rice, H.E. & Oldham, K.T. (2011) Partial splenectomy for hereditary spherocytosis: a multi-institutional review. *Journal of Pediatric Surgery*, **46**, 178–183.
- Cappellini, M.D., Robbiolo, L., Bottasso, B.M., Coppola, R., Fiorelli, G. & Mannucci, A.P. (2000) Venous thromboembolism and hypercoagulability in splenectomized patients with thalassaemia intermedia. *British Journal of Haematology*, **111**, 467–473.
- Caprotti, R., Franciosi, C., Romano, F., Codecasa, G., Musco, F., Motta, M. & Uggeri, F. (1999) Combined laparoscopic splenectomy and cholecystectomy for the treatment of hereditary spherocytosis.

- rocytosis: is it safe and effective? *Surgical Laparoscopy, Endoscopy & Percutaneous Techniques*, **9**, 203–206.
- Chapman, R.G. & McDonald, L.L. (1968) Red cell life span after splenectomy in hereditary spherocytosis. *Journal of Clinical Investigation*, **47**, 2263–2267.
- Christensen, R.D. & Henry, E. (2010) Hereditary spherocytosis in neonates with hyperbilirubinemia. *Pediatrics*, **125**, 120–125.
- Coon, W.W., Penner, J., Clagett, P. & Eos, N. (1978) Deep venous thrombosis and postsplenectomy thrombocytosis. *Archives of Surgery*, **113**, 429–431.
- Crary, S.E. & Buchanan, G.R. (2009) Vascular complications after splenectomy for hematologic disorders. *Blood*, **114**, 2861–2868.
- Csendes, A., Smok, G., Burdiles, P., Diaz, J.-C., Maluenda, F. & Korn, O. (1998) Histological findings of gallbladder mucosa in 95 control subjects and 80 patients with asymptomatic gallstones. *Digestive Diseases and Sciences*, **43**, 931–934.
- Danielson, P.D., Shaul, D.B., Phillips, J.D., Stein, J.E. & Anderson, K.D. (2000) Technical advances in pediatric laparoscopy have had a beneficial impact on splenectomy. *Journal of Pediatric Surgery*, **35**, 1578–1581.
- Davies, J.M., Lewis, M.P.N., Wimperis, J., Rafi, I., Ladhani, S. & Bolton-Maggs, P.H. (2011) Review of Guidelines for the prevention and treatment of infection in patients with an absent or dysfunctional spleen. *British Journal of Haematology*, **155**, 308–317.
- Delaunay, J. (2007) The molecular basis of hereditary red cell membrane disorders. *Blood Reviews*, **21**, 1–20.
- Delaunay, J., Stewart, G. & Iolascon, A. (1999) Hereditary dehydrated and overhydrated stomatocytosis: recent advances. *Current Opinion in Hematology*, **6**, 110–114.
- Delhommeau, F., Cynober, T., Schischmanoff, P.O., Rohrlich, P., Delaunay, J., Mohandas, N. & Tchernia, G. (2000) Natural history of hereditary spherocytosis during the first year of life. *Blood*, **95**, 393–397.
- Dhermy, D., Steen-Johnsen, J., Bournier, O., Hetet, G., Cynober, T., Tchernia, G. & Grandchamp, B. (2000) Coinheritance of two alpha-spectrin gene defects in a recessive spherocytosis family. *Clinical & Laboratory Haematology*, **22**, 329–336.
- Dutta, S., Price, V.E., Blanchette, V. & Langer, J.C. (2006) A laparoscopic approach to partial splenectomy for children with hereditary spherocytosis. *Surgical Endoscopy*, **20**, 1719–1724.
- Eber, S.W., Armbrust, R. & Schroter, W. (1990) Variable clinical severity of hereditary spherocytosis: relation to erythrocytic spectrin concentration, osmotic fragility and autohemolysis. *Journal of Pediatrics*, **117**, 409–411.
- Esposito, C., Corcione, F., Ascione, G., Garipoli, V., Di Pietto, F. & De Pasquale, M. (1998) Splenectomy in childhood. The laparoscopic approach. *Surgical Endoscopy*, **12**, 1445–1448.
- Eyssette-Guerreau, S., Bader-Meunier, B., Garcon, L., Guitton, C. & Cynober, T. (2006) Infantile pyknicocytosis: a cause of haemolytic anaemia of the newborn. *British Journal of Haematology*, **133**, 439–442.
- Farah, R.A., Rogers, Z.R., Thompson, W.R., Hicks, B.A., Guzzetta, P.C. & Buchanan, G.R. (1997) Comparison of laparoscopic and open splenectomy in children with hematologic disorders. *Journal of Pediatrics*, **131**, 41–46.
- Gallagher, P.G., Ferreira, J.D., Costa, F.F., Saad, S.T. & Forget, B.G. (2000) A recurrent frameshift mutation of the ankyrin gene associated with severe hereditary spherocytosis. *British Journal of Haematology*, **111**, 1190–1193.
- Girodon, F., Garcon, L., Bergoin, E., Largier, M., Delaunay, J., Feneant-Thibault, M., Maynadie, M., Couillaud, G., Moreira, S. & Cynober, T. (2008) Usefulness of the eosin-5'-maleimide cytometric method as a first-line screening test for the diagnosis of hereditary spherocytosis: comparison with ektacytometry and protein electrophoresis. *British Journal of Haematology*, **140**, 468–470.
- Gordon, D.H., Schaffner, D., Bennett, J.M. & Schwartz, S.I. (1978) Postsplenectomy thrombocytosis: its association with mesenteric, portal, and/or renal vein thrombosis in patients with myeloproliferative disorders. *Archives of Surgery*, **113**, 713–715.
- Gotz, M., Granditsch, G., Helmer, F., Howanietz, L. & Wagner, I.U. (1977) [Cholelithiasis in children and adolescents (authors transl)]. *Wiener Klinische Wochenschrift*, **89**, 686–690.
- Grace, R.F., Mednick, R.E. & Neufeld, E.J. (2009) Compliance with immunizations in splenectomized individuals with hereditary spherocytosis. *Pediatric Blood Cancer*, **52**, 865–867.
- Gracie, W.A. & Ransohoff, D.F. (1982) The natural history of silent gallstones: the innocent gallstone is not a myth. *New England Journal of Medicine*, **307**, 798–800.
- Hayag-Barin, J.E., Smith, R.E. & Tucker, Jr, F.C. (1998) Hereditary spherocytosis, thrombocytosis, and chronic pulmonary emboli: a case report and review of the literature. *American Journal of Hematology*, **57**, 82–84.
- Hirsh, J. & Dacie, J.V. (1966) Persistent post-splenectomy thrombocytosis and thrombo-embolism: a consequence of continuing anaemia. *British Journal of Haematology*, **12**, 44–53.
- Hoepfer, M.M., Niedermeyer, J., Hoffmeyer, F., Flemming, P. & Fabel, H. (1999) Pulmonary hypertension after splenectomy? *Annals of Internal Medicine*, **130**, 506–509.
- Iolascon, A., Faienza, M.F., Moretti, A., Perrotta, S. & Miraglia del Giudice, E. (1998) UGT1 promoter polymorphism accounts for increased neonatal appearance of hereditary spherocytosis. *Blood*, **91**, 1093.
- Iolascon, A., Delaunay, J., Wickramasinghe, S.N., Perrotta, S., Gigante, M. & Camaschella, C. (2001) Natural history of congenital dyserythropoietic anemia type II. *Blood*, **98**, 1258–1260.
- Kar, R., Mishra, P. & Pati, H.P. (2010) Evaluation of eosin-5-maleimide flow cytometric test in diagnosis of hereditary spherocytosis. *International Journal of Laboratory Hematology*, **32**, 8–16.
- King, M.J., Smythe, J.S. & Mushens, R. (2004) Eosin-5-maleimide binding to band 3 and Rh-related proteins forms the basis of a screening test for hereditary spherocytosis. *British Journal of Haematology*, **124**, 106–113.
- King, M.J., Telfer, P., MacKinnon, H., Langabeer, L., McMahon, C., Darbyshire, P. & Dhermy, D. (2008) Using the eosin-5-maleimide binding test in the differential diagnosis of hereditary spherocytosis and hereditary pyropoikilocytosis. *Cytometry. Part B, Clinical Cytometry*, **74**, 244–250.
- Mackenzie, F., Elliot, D., Eastcott, H., Hughes-Jones, N., Barkhan, P. & Mollinson, P. (1962) Relapse in hereditary spherocytosis with proven splenunculus. *Lancet*, **1**, 1102–1104.
- Mariani, M., Barcellini, W., Vercellati, C., Marcello, A.P., Fermo, E., Pedotti, P., Boschetti, C. & Zanella, A. (2008) Clinical and hematologic features of 300 patients affected by hereditary spherocytosis grouped according to the type of the membrane protein defect. *Haematologica*, **93**, 1310–1317.
- Minkes, R.K., Lagzdins, M. & Langer, J.C. (2000) Laparoscopic versus open splenectomy in children. *Journal of Pediatric Surgery*, **35**, 699–701.
- Miraglia del Giudice, E., Perrotta, S., Nobili, B., Specchia, C., d'Urzo, G. & Iolascon, A. (1999) Coinheritance of Gilbert syndrome increases the risk for developing gallstones in patients with hereditary spherocytosis. *Blood*, **94**, 2259–2262.
- Mohandas, N. & Gallagher, P.G. (2008) Red cell membrane: past, present and future. *Blood*, **112**, 3939–3948.
- Morinis, J., Dutta, S., Blanchette, V., Butchart, S. & Langer, J.C. (2008) Laparoscopic partial vs total splenectomy in children with hereditary spherocytosis. *Journal of Pediatric Surgery*, **43**, 1649–1652.
- Nikol, S., Huehns, T.Y., Kiefmann, R. & Hofling, B. (1997) Excessive arterial thrombus in spherocytosis. A case report. *Angiology*, **48**, 743–748.
- Nolan, G.R. (1984) Hereditary xerocytosis. A case history and review of the literature. *Pathology*, **16**, 151–154.
- Perrotta, S., Gallagher, P.G. & Mohandas, N. (2008) Hereditary spherocytosis. *Lancet*, **372**, 1411–1426.
- Pinto, L., Iolascon, A., Miraglia del Giudice, E., Matarese, M.R.S., Nobili, B. & Perrotta, S. (1995) The Italian pediatric survey on hereditary spherocytosis. *Journal of Paediatric Hematology/Oncology*, **2**, 43–47.
- Price, V.E., Blanchette, V.S. & Ford-Jones, E.L. (2007) The prevention and management of infections in children with asplenia or hyposplenia. *Infectious Disease Clinics of North America*, **21**, 697–710, viii–ix.
- Ravindranath, Y., Goyette, Jr, G. & Johnson, R.M. (1994) Southeast Asian ovalocytosis in an African-American family. *Blood*, **84**, 2823–2824.

- Rescorla, F.J., Engum, S.A., West, K.W., Tres Scherer, L.R. 3rd, Rouse, T.M. & Grosfeld, J.L. (2002) Laparoscopic splenectomy has become the gold standard in children. *American Surgeon*, **68**, 297–301; discussion 301–292.
- Rice, H.E., Oldham, K.T., Hillery, C.A., Skinner, M.A., O'Hara, S.M. & Ware, R.E. (2003) Clinical and hematologic benefits of partial splenectomy for congenital hemolytic anemias in children. *Annals of Surgery*, **237**, 281–288.
- Robertson, J.F., Carachi, R., Sweet, E.M. & Raine, P.A. (1988) Cholelithiasis in childhood: a follow-up study. *Journal of Pediatric Surgery*, **23**, 246–249.
- Rocha, S., Costa, E., Catarino, C., Belo, L., Castro, E.M., Barbot, J., Quintanilha, A. & Santos-Silva, A. (2005) Erythropoietin levels in the different clinical forms of hereditary spherocytosis. *British Journal of Haematology*, **131**, 534–542.
- Rocha, S., Costa, E., Rocha-Pereira, P., Ferreira, F., Cleto, E., Barbot, J., Quintanilha, A., Belo, L. & Santos-Silva, A. (2010a) Erythrocyte membrane protein destabilization versus clinical outcome in 160 Portuguese Hereditary Spherocytosis patients. *British Journal of Haematology*, **149**, 785–794.
- Rocha, S., Costa, E., Belo, L. & Santos-Silva, A. (2010b) Hereditary spherocytosis and the (TA)nTAA polymorphism of UGTA1A1 gene promoter region – a comparison of the bilirubin plasmatic levels in the different clinical forms. *Blood Cells, Molecules, and Diseases*, **44**, 117–119.
- Rutkow, I.M. (1981) Twenty years of splenectomy for hereditary spherocytosis. *Archives of Surgery*, **116**, 306–308.
- Saada, V., Cynober, T., Brossard, Y., Schischmanoff, P.O., Sender, A., Cohen, H., Delaunay, J. & Tchernia, G. (2006) Incidence of hereditary spherocytosis in a population of jaundiced neonates. *Pediatric Hematology and Oncology*, **23**, 387–397.
- Sandler, A., Winkel, G., Kimura, K. & Soper, R. (1999) The role of prophylactic cholecystectomy during splenectomy in children with hereditary spherocytosis. *Journal of Pediatric Surgery*, **34**, 1077–1078.
- Schilling, R.F. (2009) Risks and benefits of splenectomy versus no splenectomy for hereditary spherocytosis – a personal view. *British Journal of Haematology*, **145**, 728–732.
- Schilling, R.F., Gangnon, R.E. & Traver, M. (2006) Arteriosclerotic events are less frequent in persons with chronic anemia: evidence from families with hereditary spherocytosis. *American Journal of Hematology*, **81**, 315–317.
- Schilling, R.F., Gangnon, R.E. & Traver, M.I. (2008) Delayed adverse vascular events after splenectomy in hereditary spherocytosis. *Journal of Thrombosis and Haemostasis*, **6**, 1289–1295.
- Schroter, W. & Kahsnitz, E. (1983) Diagnosis of hereditary spherocytosis in newborn infants. *Journal of Pediatrics*, **103**, 460–463.
- Schwarz, K., Iolascon, A., Verissimo, F., Trede, N.S., Horsley, W., Chen, W., Paw, B.H., Hopfner, K.P., Holzmann, K., Russo, R., Esposito, M.R., Spano, D., De Falco, L., Heinrich, K., Joggerst, B., Rojewski, M.T., Perrotta, S., Denecke, J., Pannicke, U., Delaunay, J., Pepperkok, R. & Heimpel, H. (2009) Mutations affecting the secretory COPII coat component SEC23B cause congenital dyserythropoietic anemia type II. *Nature Genetics*, **41**, 936–940.
- Shao, T. & Yang, Y.X. (2005) Cholecystectomy and the risk of colorectal cancer. *American Journal of Gastroenterology*, **100**, 1813–1820.
- Smith, B.M., Schropp, K.P., Lobe, T.E., Rogers, D.A., Presbury, G.J., Wilimas, J.A. & Wong, W.C. (1994) Laparoscopic splenectomy in childhood. *Journal of Pediatric Surgery*, **29**, 975–977.
- Stewart, G.W. & Turner, E.J. (1999) The hereditary stomatocytoses and allied disorders: congenital disorders of erythrocyte membrane permeability to Na and K. *Baillieres Best Practice & Research. Clinical Haematology*, **12**, 707–727.
- Stewart, G.W., Amess, J.A., Eber, S.W., Kingswood, C., Lane, P.A., Smith, B.D. & Mentzer, W.C. (1996) Thrombo-embolic disease after splenectomy for hereditary stomatocytosis [see comments]. *British Journal of Haematology*, **93**, 303–310.
- Stoya, G., Gruhn, B., Vogelsang, H., Baumann, E. & Linss, W. (2006) Flow cytometry as a diagnostic tool for hereditary spherocytosis. *Acta Haematologica*, **116**, 186–191.
- Tanoue, K., Okita, K., Akahoshi, T., Konishi, K., Gotoh, N., Tsutsumi, N., Tomikawa, M. & Hashizume, M. (2002) Laparoscopic splenectomy for hematologic diseases. *Surgery*, **131**, S318–S323.
- Tchernia, G., Gauthier, F., Mielot, F., Dommergues, J.P., Yvart, J., Chasis, J.A. & Mohandas, N. (1993) Initial assessment of the beneficial effect of partial splenectomy in hereditary spherocytosis. *Blood*, **81**, 2014–2020.
- Tchernia, G., Bader-Meunier, B., Berterottiere, P., Eber, S., Dommergues, J.P. & Gauthier, F. (1997) Effectiveness of partial splenectomy in hereditary spherocytosis. *Current Opinion in Hematology*, **4**, 136–141.
- Tchernia, G., Delhommeau, F., Perrotta, S., Cynober, T., Bader-Meunier, B., Nobili, B., Rohrlisch, P., Salomon, J.L., Sagot-Bevenot, S., del Giudice, E.M., Delaunay, J., DeMattia, D., Schischmanoff, P.O., Mohandas, N. & Iolascon, A. (2000) Recombinant erythropoietin therapy as an alternative to blood transfusions in infants with hereditary spherocytosis. *The Hematology Journal*, **1**, 146–152.
- Tse, W.T., Gallagher, P.G., Jenkins, P.B., Wang, Y., Benoit, L., Speicher, D., Winkelmann, J.C., Agre, P., Forget, B.G. & Marchesi, S. (1997) Amino acid substitution in alpha-spectrin commonly co-inherited with nondominant hereditary spherocytosis. *American Journal of Hematology*, **54**, 233–241.
- Tuffy, B., Brown, A.K. & Zuelzer, W.W. (1959) Infantile pyknocytosis, a common erythrocyte abnormality of the first trimester. *American Journal of Diseases of Children*, **98**, 227–241.
- Vasilescu, C., Stanculea, O., Tudor, S., Stanescu, D., Colita, A., Stoia, R., Coriu, D. & Arion, C. (2006) Laparoscopic subtotal splenectomy in hereditary spherocytosis: to preserve the upper or the lower pole of the spleen? *Surgical Endoscopy*, **20**, 748–752.
- Vives Corrons, J.L., Besson, I., Aymerich, M., Ayala, S., Alloisio, N., Delaunay, J., Gonzalez, I. & Manrubia, E. (1995) Hereditary xerocytosis: a report of six unrelated Spanish families with leaky red cell syndrome and increased heat stability of the erythrocyte membrane. *British Journal of Haematology*, **90**, 817–822.
- Wichterle, H., Hanspal, M., Palek, J. & Jarolim, P. (1996) Combination of two mutant alpha spectrin alleles underlies a severe spherocytic hemolytic anemia. *Journal of Clinical Investigation*, **98**, 2300–2307.