

AN ACUTE FEBRILE PLEIOCHROMIC ANEMIA WITH
HYALINE THROMBOSIS OF THE TERMINAL
ARTERIOLES AND CAPILLARIES

AN UNDESCRIBED DISEASE *

ELI MOSCHCOWITZ, M.D.

NEW YORK

This case is remarkable, clinically and anatomically.

REPORT OF CASE

History—K. Z., a girl, aged 16 years, was an elementary school graduate, had gone to business school, and had been employed for eight months preceding the illness. There were three other children, two younger and one older; all apparently were perfectly normal. There were no home difficulties, and poverty was not extreme. She had spent September 4 and 5 at Rockaway Beach, where she appeared in perfect health and spirits. She had returned home on the evening of September 5 and slept well. On the morning of September 6, she complained of weakness in the upper extremities and had pain on moving the wrists and elbows; she already had marked pallor and was slightly constipated. The symptoms increased in severity until she was admitted to the Beth Israel Hospital, September 15. While at home, she had a constant fever, the temperature rising once to 104 F. and staying at other times between 101 and 102. F.

Physical Examination.—The patient was a pale girl with "café au lait" tinge. A few petechiae were present on the left arm. The lungs and heart revealed nothing abnormal. The spleen and liver were not enlarged. The abdomen was lax and not tender. September 18, the red blood count was 1,330,000; the hemoglobin, 40 per cent.; the leukocytes, 12,600, of which 65 per cent. were polymorphonuclears. The red cells revealed a central pallor, but there were no nucleated elements. A fragility test showed hemolysis to begin at 0.8, and to be complete at 0.19 (?). No platelet count was made. September 19, the red blood count was 1,120,000; the hemoglobin was 40 per cent., and the leukocytes were 19,000. A blood culture remained sterile.

The urine showed marked traces of albumin with hyaline and granular casts.

The blood chemistry, September 16, showed: urea, 21.2 mg. per hundred cubic centimeters; nonprotein nitrogen, 31.25 mg. per hundred cubic centimeters, and creatinin, 1.1 mg. per hundred cubic centimeters. The feces and gastric contents gave a marked reaction for occult blood.

Roentgen-ray examination of the chest showed nothing abnormal. The electrocardiogram showed inversion of the T wave in Lead III. The temperature, on admission, was 101.8 F. During the week the patient was in the hospital, it ranged between 100 and 102 F. The pulse varied between 100 and 130. The respiration was around 20. The systolic blood pressure was 130, and the diastolic, 60.

September 19, there was partial paresis of the left arm and leg; also, a slight facial paralysis. The following day, a double Kernig reflex was noted. That night there was pulmonary edema, which responded to treatment. Soon after, the patient went into coma; respirations became irregular, and she died, September 20. Dr. E. Libman, who saw this patient in consultation, recognized the condition as a new disease.

* Read before the New York Pathological Society, Feb. 7, 1924.

Necropsy.—A partial necropsy was done. The body was pale and poorly nourished. The lower lobes of both lungs showed marked congestion. The heart was slightly enlarged; the left ventricle was hypertrophied; the muscle was firm and pale. The mitral and aortic valves were normal. The liver was slightly enlarged, pale and fatty; there was slight nutmeg change. The spleen measured 11 by 8 by 3 cm., and weighed 165 gm. The surface was smooth. On section, the organ was deep mahogany red, somewhat soft and velvety. The malpighian bodies were prominent. The kidneys were large; the capsules were smooth and not adherent; on section, the organ was deep red.

The anatomical diagnosis was anemia; acute congestion at the bases of both lungs; hypertrophy of the left ventricle of the heart; hyperplasia of the spleen, and congestion of the liver and the kidneys.

Microscopic Examination.—The lungs were edematous; at the bases, there was congestion of the parenchyma. The heart muscle revealed a striking

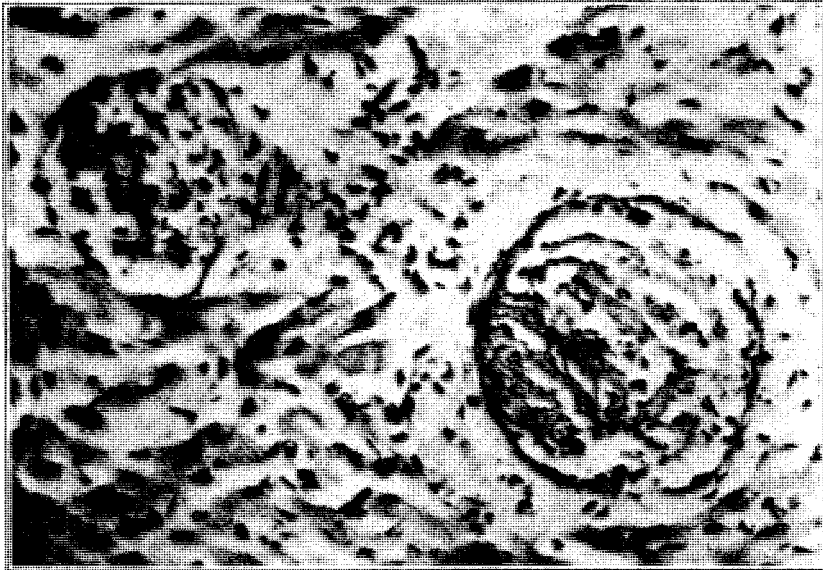


Fig. 1.—Section of heart muscle, showing hyaline thrombi in early stage.

appearance. With the low power of the microscope, practically every field revealed from one to a dozen structures that were unquestionably thrombi in the terminal arterioles or capillaries. These varied in appearance and revealed progressive changes depending on the amount of organization that had taken place. The earliest (Fig. 1) showed merely a plugging of the vessel with a hyaline mass which either partially or completely filled the lumen. Usually, even in this stage, the plug, if not in intimate contact with the wall of the vessel, was surrounded by a layer of flat cells of the fibroblastic type which was distinct from the endothelial intima. In older plugs (Figs. 2 and 3), fibroblasts penetrated into the hyaline mass, and the older the plug, the greater became the amount of fibroblastic infiltration at the expense of the hyaline material; eventually, a small fibroblastic tubercle-like structure was formed. In some of these thrombi, the origin of these fibroblasts from the endothelium of the vessel was plainly discernible. At the same time, the process of organization within the lumen was accompanied by a fibroblastic process around the wall of the vessel in concentric fashion; with the van Gieson stain, some gave the reaction for fibrous tissue. Karyo-

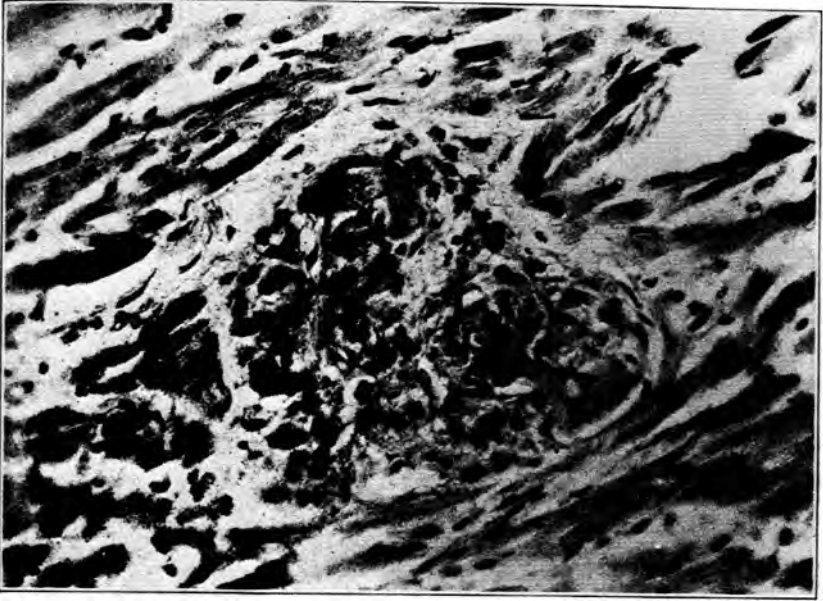

Fig. 2.—Section of heart muscle, showing hyaline thrombi with beginning organization.

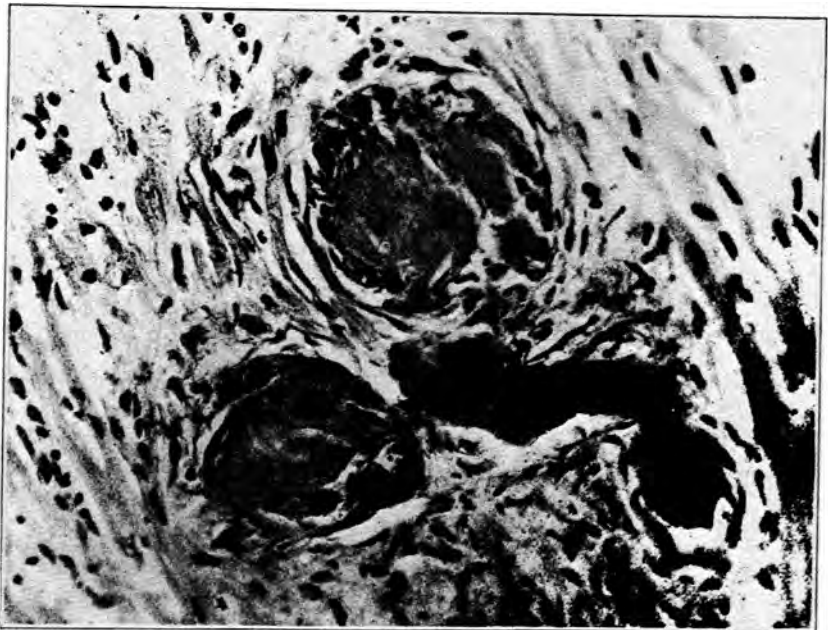


Fig. 3.—Section of heart muscle, showing hyaline thrombi with beginning organization.

kinetic figures in these fibroblasts were common. In some vessels in which the plug had not completely filled the lumen, tiny spaces were formed in which fresh red cells were visible. Only the terminal arterioles and capillaries were involved. The larger vessels with well defined muscular walls showed no change whatever, either in the form of thrombosis or changes in the intima. Every section of heart muscle was involved, the ventricles, the auricles, the papillary muscles and the septum; they were even visible in some of the vessels of the precordial fat. In addition, there was moderate edema of the parenchyma. The liver showed a moderate fatty infiltration and slight congestion around the central veins. Very few hyaline thrombi in the early stages were noted. The spleen showed enormous congestion of the sinuses. A few hyaline thrombi were present in some of the central vessels of the malpighian bodies. The kidneys showed marked parenchymatous degeneration in the tubules and congestion of the parenchyma. The malpighian tufts were

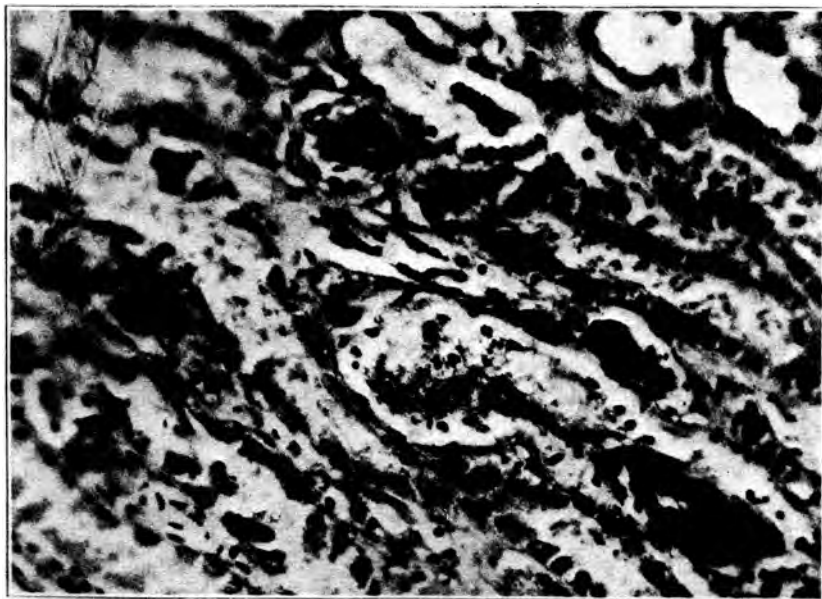


Fig. 4.—Section of kidney, showing hyaline thrombi in terminal arterioles.

clear. Many of the arterioles and capillaries in the middle zone, in the region of the vasa recta, showed hyaline thrombi of the same morphology as those in the heart (Fig. 4). No bacteria, tubercle bacilli or spirocheta pallida were found in any of the tissues.

A fairly complete search of the medical literature fails to reveal a case resembling this, either clinically or anatomically. Hyaline thrombi have long been recognized but never in respect to the enormous spread and distribution revealed in this case. Klebs¹ apparently was the first to describe these thrombi; he noted them in cases of extensive burns. They have been described in a wide variety of conditions. Thus, Kaufman² found capillary red cell thrombi in cases of mercury poison-

1. Klebs: *Handb. d. path. Anat. Berlin*, **2**:114, 1868-1880.

2. Kaufman, quoted by Dietreich (Footnote 6).

ing. Schmorl³ found them in the stomach and liver after abrin poisoning. Flexner⁴ noted such thrombi in the neighborhood of ulcerated typhoid ulcers of the ileum and in the lung, associated with bronchiectasis; also in the liver in eclampsia, and in the stomach after carbolic acid poisoning. He also states that they have been found in pneumonia, diphtheria and in some of the acute infectious diseases. Loeb, Stricker and Tuttle⁵ noted red cell thrombi in the lungs of animals after the injection of a foreign serum. Dietreich⁶ found such thrombi in animals after the injection of an extract from beans. Bacterial infections are common causes of such thrombi, for they have been produced experimentally, in infections, by the hog cholera bacillus (Boxmeyer⁷), the pneumococcus and the staphylococcus aureus.

The true pathogenesis of hyaline thrombi was not known until Flexner showed that they arose from agglutinated red cells. This he proved by injecting the highly agglutinative substance, ricin, into rabbits. He concludes that when red cell thrombi are old or when agglutination is compact, they have the appearance of hyaline thrombi. He also states that poisons that destroy red blood corpuscles rapidly provoke agglutinative thrombi, and that the so-called fibrin ferment thrombi are probably agglutinative thrombi. Pearce,⁸ indeed, obtained hyaline thrombi in the liver associated with focal necroses by injecting agglutinating serums. He also injected filtered autolyzed products of various bacteria which possess hemagglutinins of low activity and obtained similar necroses of the liver associated with fused red blood cell thrombi, i. e., structures resembling hyaline thrombi.

In this condition, it is interesting to note that, as far back as 1875, Landois⁹ found that an injection of foreign blood causes multiple capillary thrombosis.

I have learned that Dr. Max Lederer of Brooklyn has seen four cases clinically identical with the one described in this report. He permits me to state that, thus far, no cause has been found, and that all four patients recovered promptly after a single transfusion of blood.

From these observations we conclude that death, in the case described, resulted from some powerful poison which had both agglutinative and hemolytic properties. If opportunity offers, further investigation will be made of this strange disease with strange pathologic morphology.

3. Schmorl: Jahresb. d. Gessellsch. f. Nat.-u. Heilk. in Dresd., 1899-1900, quoted by Flexner (Footnote 4).

4. Flexner: J. M. Res. **8**:316, 1902.

5. Loeb, Stricker and Tuttle: Virchows Arch. f. path. Anat. **201**:5, 1910.

6. Dietreich: Centralbl. f. Path. **23**:372, 1912.

7. Boxmeyer: J. M. Res. **9**:146, 1903.

8. Pearce and Winne: Am. J. M. Sc. **128**:669, 1904.

9. Landois: Die Tranfusion des Blutes, Leipzig, 1875, p. 225.